

TREATMENT OF FULL-THICKNESS ARTICULAR CARTILAGE LESIONS OF THE KNEE IN HIGH-DEMAND ATHLETES WITH AUTOLOGOUS CHONDROCYTE TRANSPLANTATION

KAI MITHOEFER, MD *, THOMAS J. GILL, MD *, ERIC GIZA, MD *, BERT R. MANDELBAUM, MD †, LARS PETERSON, MD, PhD ‡, TOM MINAS, MD*

* HARVARD COMBINED ORTHOPEDIC SURGERY PROGRAM, BOSTON, USA, †SANTA MONICA ORTHOPEDIC AND SPORTS MEDICINE FOUNDATION, SANTA MONICA, USA, ‡GOTHENBURG MEDICAL CENTER, GOTHENBURG, SWEDEN

INTRODUCTION

Soccer is the most popular sport worldwide with about 200 million currently registered active players.¹ The frequency of soccer injuries is estimated at 10-35 per 1000 hours of competition, with the majority occurring in the lower extremities. Knee injuries account for 15-40% of soccer-related injuries.^{2,3}

While numerous studies have described injuries of the cruciate ligaments and menisci in soccer players, little information is available on articular cartilage injuries in these high-demand athletes.⁴ This lack of data is surprising since the prevalence of acute and chronic articular cartilage lesions in the cruciate-deficient knee is well documented.^{5,6} The lack of available data on cartilage lesions in soccer players is not completely understood, but may be related to the limited treatment options available for these injuries in the past. Levy and coworkers have recently confirmed the increasing frequency of isolated chondral injuries in collegiate, professional and world-class soccer players. They concluded that the observed increase resulted from both the growing popularity of the sport and the increased awareness of chondral injuries due to emerging new techniques for cartilage repair.⁴

In full-thickness injuries to the articular cartilage, disruption of the articular surface occurs without concomitant violation the subchondral bone, which precludes access to the subchondral vasculature. Since no bleeding occurs, the avascular

cartilage can only promote repair via a transient increase in mitotic and metabolic activity in the surviving chondrocytes bordering the defect. Due to this limited response, the newly synthesized matrix is nearly always insufficient to fill the defect and restore the articular surface. Laboratory studies have shown that because of the qualitative and quantitative deficiencies in the spontaneous repair tissue, the newly formed matrix deteriorates quickly with loading of the joint surface.⁷ Clinically, this leads to progression of the lesions, with pain, swelling, catching of the joint, and a dramatic reduction of the patient's quality of life and ability to participate in athletic activities.⁸

Repair of articular cartilage has been difficult due to the pathophysiology and molecular biology of cartilage tissue, and traditional treatment methods have not produced reliable and lasting results.^{9,10} The treatment of articular cartilage lesions in the knee has recently gained considerable interest due to the development of new techniques. The successful repair of articular cartilage lesions of the human knee by autologous chondrocyte transplantation was first reported by Brittberg in 1994.¹¹ Recent follow-up data demonstrates excellent results with the use of this technique up to eleven years.^{12,13} However, an evaluation of autologous chondrocyte transplantation in high-demand athletes, such as soccer players, has not yet been performed.

METHODS

Soccer players with acute or chronic articular cartilage lesions were treated with autologous chondrocyte transplantation at Brigham and Women's Hospital, Boston, MA, Santa

Kai Mithoefer, MD is a Resident, Harvard Combined Orthopaedic Residency Program.

Eric Giza, MD is a Resident, Harvard Combined Orthopaedic Residency Program.

Tom Gill, MD is an Attending Physician, Massachusetts General Hospital and an Assistant Professor of Orthopaedic Surgery, Harvard Medical School.

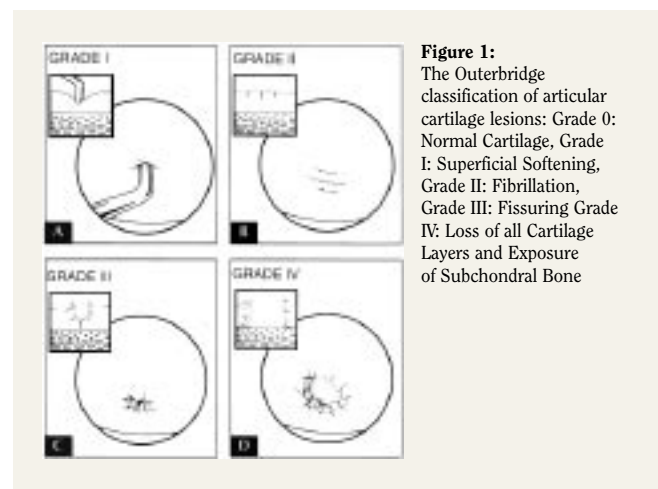
Bert R. Mandelbaum, MD is an Orthopaedics Surgeon, Santa Monica Orthopaedic and Sports Medicine Group, Santa Monica, California.

Tom Minas, MD is Director, Cartilage Repair Center, Brigham and Women's Hospital and an Associate Professor, Harvard Medical School.

Lars Peterson, MD is an Attending Physician, Department of Orthopaedic Surgery Gothenburg Medical Center, Gothenburg, Sweden.

Address correspondence to:

Tom Minas, MD
Brigham and Women's Hospital
75 Francis Street
Boston, MA 02115
617-732-5377
tminas@partners.org



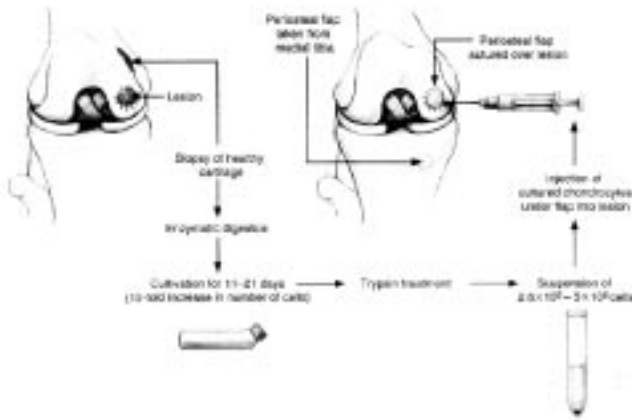


Figure 2: Procedure of Autologous Chondrocyte Transplantation including cartilage biopsy, procurement, culture of chondrocytes, and re-implantation under fibrin-sealed periosteal flap.

Monica Orthopedic Sports Medicine Foundation, Los Angeles, CA and Gothenburg Medical Center, Gothenburg, Sweden. The athletes were examined and completed functional outcome questionnaires preoperatively and at defined postoperative intervals. Data analysis included gender, associated injuries, skill level, previous injuries or trauma, and clinical symptoms. Intraoperative data was collected from operative notes and available intraoperative video recordings and photographs to determine anatomic location, defect size and grade. Articular cartilage lesions were graded using the most widely accepted depth classification system described by Outerbridge (Figure 1).¹⁴

Autologous chondrocytes were harvested from a non-weightbearing area of the knee joint. The cells were then cultured and multiplied *in vitro* followed by reimplantation after 3-4 weeks. At implantation, the cultured chondrocytes were placed under a periosteal flap covering the articular cartilage defect and sealed with a thin fibrin layer (Figure 2). Local growth factors stimulate the chondrocytes to produce an extracellular cartilage matrix that closely resembles hyaline cartilage. Results of a recent multicenter study demonstrated good to excellent results in up to 92% after 2-11 years following autologous chondrocyte transplantation.^{12,13} Rehabilitation was performed according to previously described protocols.¹⁵

Functional outcome was evaluated by use of scientifically established knee rating systems including the Modified Cincinnati Knee Score, Western Ontario McMaster Index (WOMAC), and Knee Society Score. Data analysis was performed by standard statistical methods using established commercially available software (SPSS Inc., Chicago, IL, USA). Differences were considered significant at a probability level of 95% ($P < 0.05$).

RESULTS

Over 20 amateur soccer players were treated with autologous chondrocyte transplantation (ACT). Range of player age at the time of transplantation was 14-43 years. There was minimum 6 month follow-up. Roughly one half of players

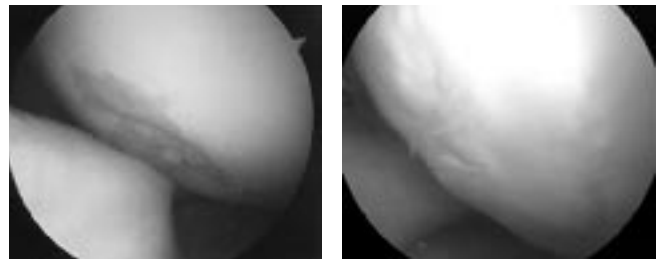


Figure 3. Arthroscopic view demonstrating a contained full-thickness defect of the articular cartilage of the lateral femoral condyle in a soccer player before (left) and after treatment with autologous chondrocyte transplantation (right).

presented with ACL deficiency or history of previous ACL reconstruction. The predominant symptom was pain, and catching or locking was noted in just under half of the patients studied. Lesions varied in size from 1.5 to 20 cm². Almost half of the lesions were located on the medial femoral condyle, with lateral femoral condyle, lateral tibial plateau, trochlear, and patellar lesions also noted. Single lesions predominated (Figure 3). Additional procedures included high tibial osteotomy, ACL-reconstruction, meniscal repair, and tibial tubercle osteotomy. Seventy percent of all players rated their results as good or excellent by overall clinical evaluation. The rate of good or excellent results was higher in players with single cartilage lesions or defects located on the medial femoral condyle. Modified Cincinnati scores, Western Ontario MacMaster (WOMAC) Scores, and Knee Society Scores all improved significantly. No association was found between the functional outcome and gender, age, defect location, defect size, defect number, or presence of anterior cruciate ligament deficiency. Failure of the repair occurred in under 15 percent of patients. Graft delamination was noted in one patient.

DISCUSSION

Autologous chondrocyte transplantation has been described as a successful technique for the restoration of full-thickness articular cartilage lesions in the knee by several investigators.⁹⁻¹² Recent data indicates excellent long-term durability of articular cartilage restoration and persistence of improved knee function up to eleven years after surgery.¹³ Besides autologous chondrocyte transplantation, other techniques for repair of articular cartilage defects have been used successfully such as microfracture^{16,17} and osteochondral mosaicplasty¹⁸. While the mosaicplasty and microfracture technique has been evaluated in athletes^{18,19} an assessment of autologous chondrocyte transplantation in the athletic population has not yet been performed.

The soccer population was chosen to test the effect of autologous chondrocyte transplantation since the increased risk for development of knee osteoarthritis in this high-demand athletic population is well documented, particularly at the elite level.²⁰⁻²³ A recent consensus conference on osteoarthritis at the National Institute of Health (NIH) demonstrated a relative risk of 4.4-5.3 for knee osteoarthritis in soccer players.²⁴ This fivefold increased risk for gonarthrosis likely results from the high joint stresses associated with repetitive joint

impact and torsional loading from rapid deceleration motions, frequent pivoting, and player contact. Besides chronic cartilage degeneration, acute injuries to the articular cartilage of the knee can have a profound impact on the player's career, representing the most common cause of permanent disability.²⁵ Thus, management of chondral lesions in the knee in this high-demand population may play a crucial role in limiting or preventing severe long-term sequelae.²⁶

Acute or chronic injuries of the anterior cruciate ligament were reported in approximately half of our patients. This is consistent with the previously described high incidence of soccer-related anterior cruciate ligament (ACL) injuries. Anterior cruciate ligament injuries are associated with articular cartilage lesions in 40-70% and these lesions are frequently located on the femoral condyle.⁵ Accordingly, the articular cartilage lesions in soccer players in our study presented primarily as isolated lesions of the medial or lateral femoral condyle. In contrast to previous studies,¹² no significant differences were observed between players with isolated or multiple lesions, but this may be related to the relatively low number

of athletes with multiple articular cartilage defects in our study population. The percentage of good to excellent results in soccer players falls within the previously reported range of 65-92% good to excellent results for autologous chondrocyte transplantation in the general patient population.^{12,13} As observed in previous studies of this technique, isolated lesions of the femoral condyle in soccer players were associated with better outcomes.

SUMMARY

Our data indicates that the early results from repair of full-thickness articular cartilage lesions in high-demand athletes are comparable to the results reported for microfracture¹⁹ or osteochondral mosaicplasty¹⁸. The current results represent a preliminary report of an ongoing study. Further investigation is under way to determine the long-term functional outcome and ability to return to competition in this highly demanding sport. Long-term evaluation will help to determine whether restoration of articular cartilage lesions in the knee in soccer players can effectively reduce the high incidence of osteoarthritis in soccer players.

References

1. Dvorak J, Graf-Baumann T, Peterson L, Junge A. Editorial. *Am J Sports Med* 2000; 28: S1-2.
2. Peterson L, Junge A, Chomiak J, Graf-Baumann T, Dvorak J. Incidence of football injuries and complaints in different age groups and skill-level groups. *Am J Sports Med* 2000; 28:S51-57.
3. Muckle DS. Injuries in professional footballers. *Br J Sports Med* 1981; 15:77-79.
4. Levy AS, Lohnes J, Sculley S, LeCroy M, Garrett W. Chondral delamination of the knee in soccer players. *Am J Sports Med* 1996; 24:634-39.
5. Kohn D. Arthroscopy in acute injuries of anterior cruciate-deficient knees with fresh and old intraarticular lesions. *Arthroscopy* 1986; 2:98-102.
6. Zamber RW, Teitz CC, McGuire DA, Frost JD, Hermanson BK. Articular cartilage lesions of the knee. *Arthroscopy* 1989; 5:258-268.
7. Frenkel SR, DiCesare PE. Degradation and repair of articular cartilage. *Front Biosci* 1999; 4:671-685.
8. Minas T. Chondrocyte Implantation in the reparation of chondral lesions of the knee: Economics and Quality of Life. *Am J Orthopedics* 1998; 24:739-744.
9. Minas T. The role of cartilage repair techniques, including chondrocyte transplantation, in focal chondral knee damage. *AAOS Instr Course Lect* 1999; 48:629-643.
10. Mandelbaum BT, Browne JE, Fu F, Micheli L, Mosley JB, Erggelet C, Minas T, Peterson L. Articular Cartilage lesions of the knee. *Am J Sports. Med* 2000; 26: 853-861.
11. Brittberg M, Lindahl A, Nilsson A, Peterson L. Treatment of deep cartilage defects in the knee with autologous chondrocyte transplantation. *N Engl J Med* 1994; 331:889-895.
12. Peterson L, Minas T, Brittberg M, Nilsson A, Sjögren-Jansson, Lindahl A. Two-to 9-year outcome after autologous chondrocyte transplantation of the knee. *Clin Orthop* 2000; 374:212-234.
13. Peterson L, Brittberg M, Kiviranta I, Akerlund EL, Lindahl A. Autologous chondrocyte transplantation. Biomechanics and long-term durability. *Am J Sports Med* 2002; 30:2-12.
14. Outerbridge RE. The etiology of chondromalacia patellae. *J Bone Joint Surg* 1961; 43B752-767.
15. Minas T, Peterson L. Autologous chondrocyte transplantation. *Oper Tech Sports Med* 2000; 8:144-157.
16. Gill TJ. The treatment of articular cartilage defects using microfracture and debridement. *Am J Knee Surg* 2000; 13:33-40.
17. Steadman JR, Rodkey WG, Singleton SB, Briggs KK. Microfracture technique for full thickness chondral defects: Technique and clinical results. *Oper Tech Orthopedics* 1997; 7:300-304.
18. Kish G, Modis L, Hangody L. Osteochondral mosaicplasty for the treatment of focal chondral and osteochondral lesions of the knee and talus in the athlete. *Clin Sports Med* 1999; 18:45-67.
19. Blevins FT, Steadman JR, Rodrigo JJ, Silliman J. Treatment of articular cartilage defects in athletes: an analysis of functional outcome and lesion appearance. *Orthopedics* 1998; 21:747-52.
20. Kujala UM, Kettunen J, Paananen H, Aalto T, Battie MC, Impivaara O, Videman T, Sarna S. Knee Osteoarthritis in former runners, soccer players, weight lifters, and shooters. *Arth Rheum* 1995; 38:539-546.
21. Roos H, Lindberg H, Ornell M. Soccer as a cause of hip and knee osteoarthritis. *Ann Rheum Dis* 1996; 55:690-698.
22. Drawer S, Fuller CW. Propensity for osteoarthritis and lower limb joint pain in retired professional soccer players. *Br J Sports Med* 2001; 35:402-408.
23. Larsen E, Jensen PK, Jensen PR. Long-term outcome of knee and ankle injuries in elite football players. *Scand J Med Sci Sports* 1999; 9:285-289.
24. Felson DT. Osteoarthritis: New Insights. Part 1: The disease and its risk factors. *Ann Intern Med.* 2000; 133:635-646.
25. Engstrom B, Forsblad M, Johansson C, Tornqvist H. Does a major knee injury definitely sideline an elite soccer player? *Am J Sports Med* 1990; 18:101-105.
26. Roos H. Are there long-term sequelae from soccer? *Clin Sports Med* 1998; 17:819-830.