

# MEDIAL SUBVASTUS APPROACH TO THE KNEE: SURGICAL TECHNIQUE

NATHAN K. ENDRES, MD, TOM MINAS, MD

BRIGHAM AND WOMEN'S HOSPITAL

## INTRODUCTION

There has been a recent emphasis on minimally invasive and muscle sparing approaches in orthopaedic surgery. The subvastus approach to the knee joint has been described as an alternative to traditional approaches which involve a large arthrotomy with partial division of the quadriceps mechanism. The most common application of the subvastus approach is in total knee arthroplasty. While concerns have been raised regarding intraoperative visualization and proper component positioning, promising results have been recently reported suggesting improved early recovery with equivalent complication rates.

This paper details the step-by-step surgical technique for the medial subvastus approach to the knee. As with any procedure, patient selection is paramount to success and not all patients are appropriate for this approach. However, in patients who meet our criteria, we feel that this approach offers significant benefit to patients over traditional approaches. These include less post-operative pain and easier, quicker rehabilitation in the early post-operative period. The long-term benefits, if any, are unknown.

## SURGICAL TECHNIQUE

The senior author performs a medial subvastus approach whenever possible, however some patients are better served with a standard medial parapatellar approach. Suitable candidates for a subvastus approach must have relatively mobile subcutaneous tissues in order to create a "mobile window" for performing the various aspects of the planned procedure. The mobility of the soft tissues can be assessed during a pre-operative clinic visit, but the ultimate decision is made on the day of surgery with the patient under anesthesia. Obesity, con-

Nathan K. Endres, MD, Fellow, Sports and Shoulder Service,  
Brigham and Women's Hospital, Boston, MA  
Tom Minas, MD, Associate Professor, Harvard Medical School, Director,  
Cartilage Repair Center, Brigham and Women's Hospital, Boston, MA

Address Correspondence to:

Department of Orthopedic Surgery  
Brigham and Women's Hospital  
75 Francis Street, PBB A-2  
Boston, MA 02115

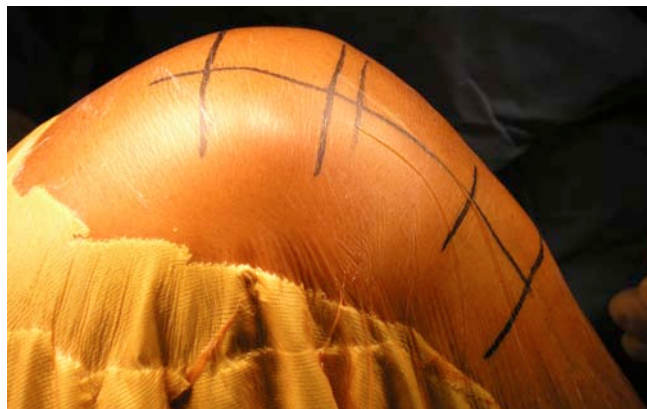

Figure 1. Typical skin incision extending from the superior pole of the patella to the tibial tubercle.

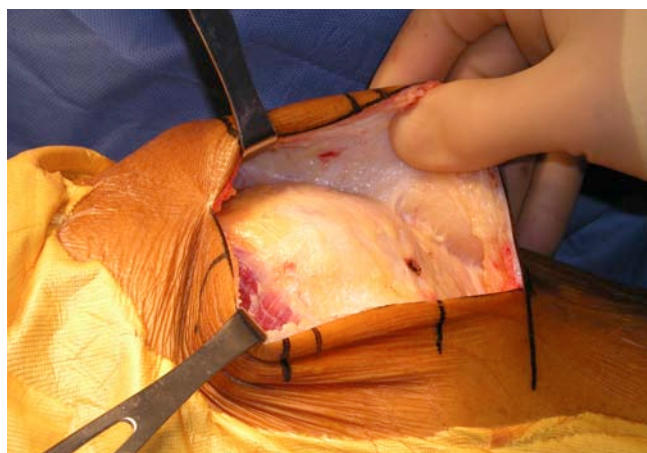


Figure 2. Development of medial and lateral full-thickness subcutaneous flaps

tractures and deformity are relative contraindications, however, with experience, the indications can be expanded. Revision surgery is usually a contraindication due to scar tissue formation and obliteration of tissue planes.

The patient is positioned supine in the standard fashion. We generally employ a lateral post at the level of the greater trochanter as well as a post to support the foot, such that the knee can be flexed and maintained at 90 degrees of flexion. The skin incision can be made directly midline or slightly medial to midline, depending on the nature of the pathology. The length of the incision is based on the underlying pathology. Generally, it extends from the superior pole of the patella to the inferior aspect of the tibial tubercle (Figure 1). The incision is carried sharply through the subcutaneous tissue down to the retinacular tissue. Full-thickness medial and lateral flaps are then created sharply with careful hemostasis (Figure 2). The

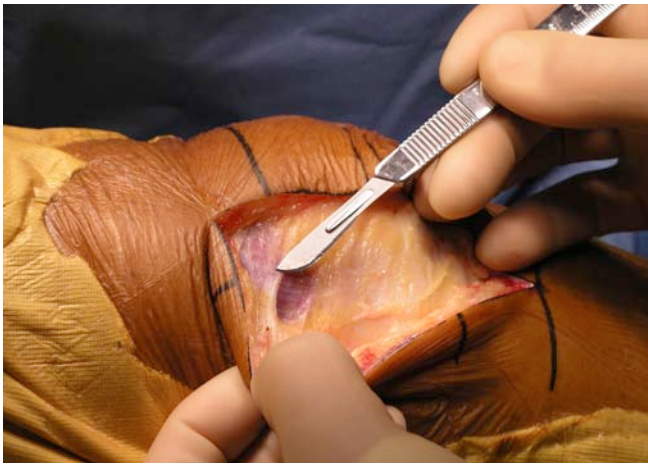


Figure 3. Exposure of VMO insertion.

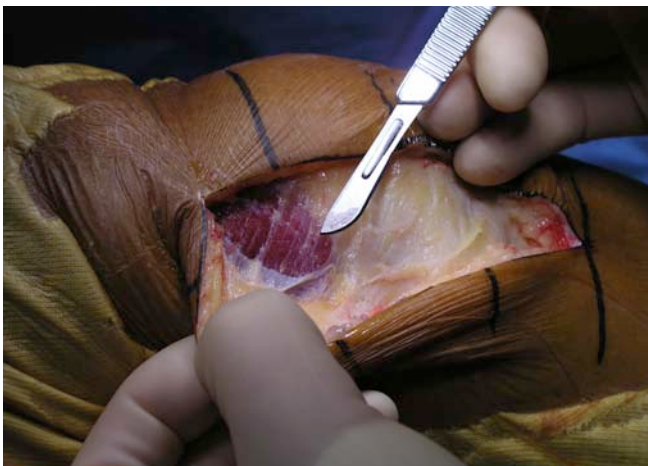


Figure 4. Subfascial dissection of VMO

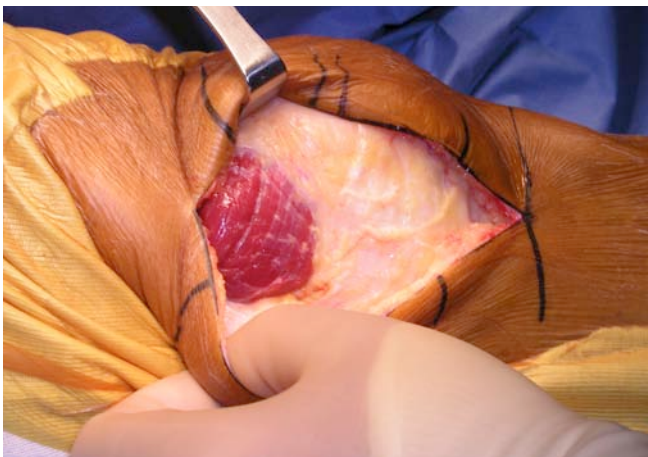


Figure 5. Complete exposure of distal VMO insertion

creation of large, full-thickness flaps is important because this allows the extensor mechanism to be mobilized deep to the subcutaneous tissues.

The distal insertion of the vastus medialis obliquus (VMO) on the patella is exposed (Figure 3). The fascia overlying the VMO is released sharply, taking care not to injure any underlying muscle fibers (Figure 4). The fascia is released

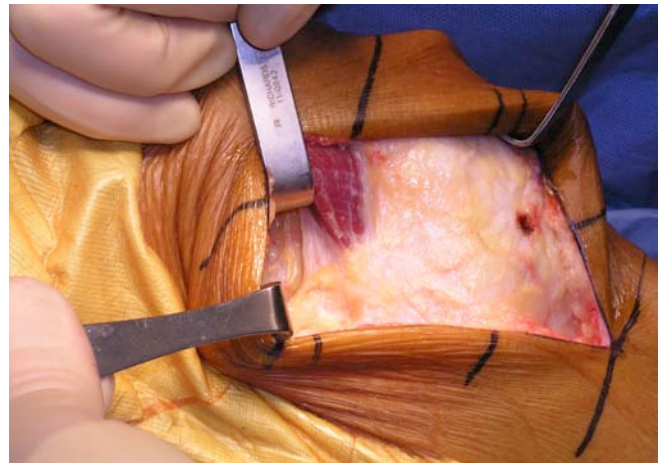


Figure 6. Placement of Z retractor underneath distal VMO. Note that the insertion on the patella is left completely intact.

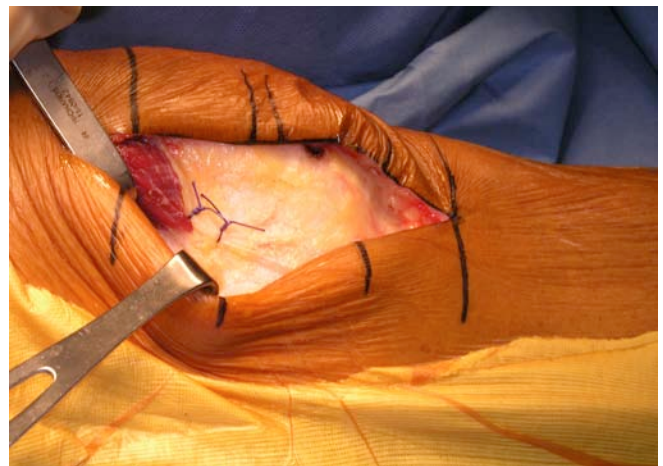
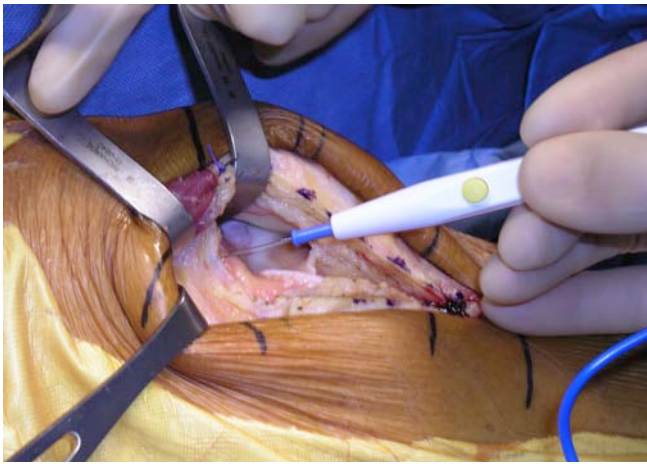


Figure 7. Tagging sutures marking distal extent of the insertion of VMO on patella

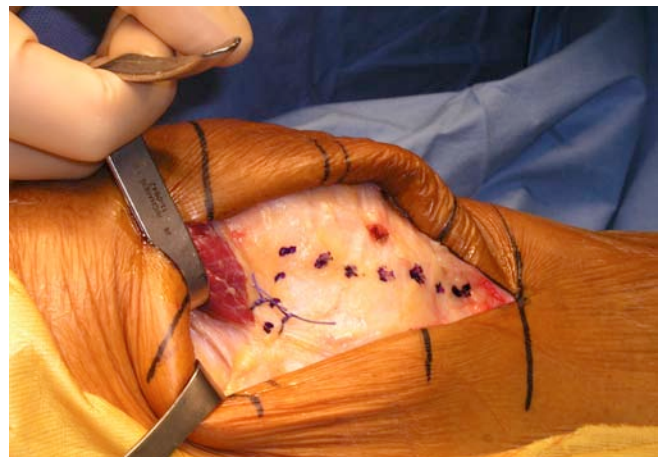

Figure 8. Proposed line of incision for performing medial arthrotoomy

posteriorly towards the attachment of the VMO on the medial intermuscular septum. This exposes the entire distal extent of the VMO (Figure 5). Using blunt dissection, a finger can be placed underneath the VMO at its inferior border. The VMO is then retracted proximally and laterally while maintaining its attachment to the patella. A Z-retractor is inserted anterior to the distal femur and deep to the muscle to maintain retraction (Figure 6).



**Figure 9.** Release of the synovial attachments from the femur to the undersurface of the quadriceps. This is done from medial to lateral. The superior retractor is placed above the synovial attachments, while the inferior retractor is intra-articular. This clearly delineates the synovial tissue that must be released to mobilize the extensor mechanism and expose the joint.

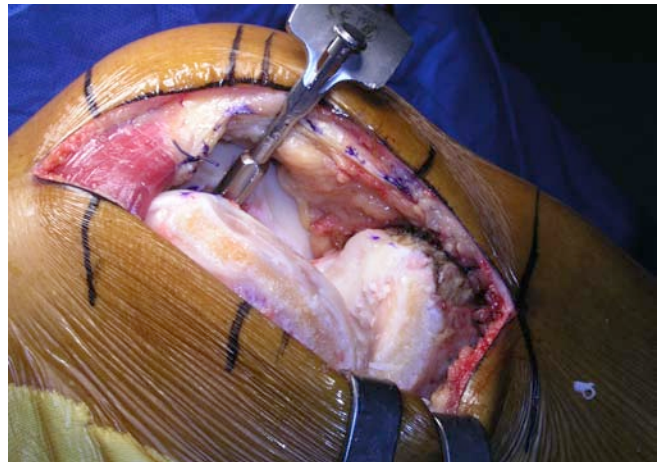
Two #1 Vicryl marking sutures are placed at the level of the VMO attachment to the patella (Figure 7). An oblique capsular incision is then made just distal to the VMO, beginning posteriorly at the level of the intermuscular septum and extending laterally, parallel to the inferior border of the muscle, towards the medial border of the patella. The incision is made between the marking sutures, which then serve as a guide for later repair. At the medial border of the patella, the arthrotomy is extended distally, taking care to leave a cuff of tissue attached to the patella for closure (Figure 8)

The arthrotomy incision is carried distally across the joint line and parallel to the medial border of the patellar tendon. Care is taken to avoid damaging the anterior horn of the medial meniscus if a biologic procedure is being performed. If necessary, the retropatellar bursa and fat pad can be incised to gain additional exposure.

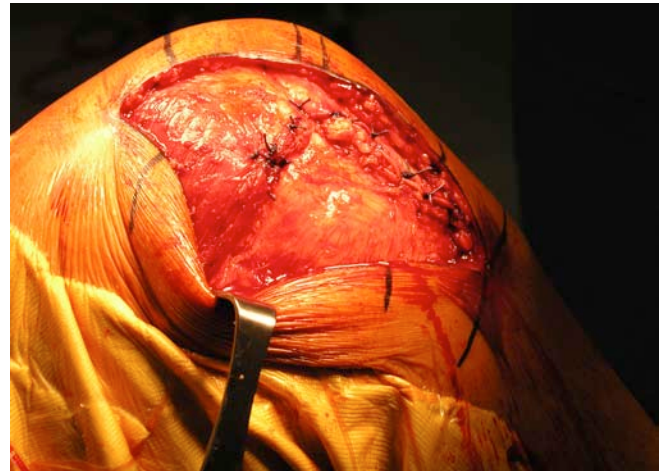Next, attention is turned to the suprapatellar pouch where the synovial capsular attachments to the undersurface of the quadriceps tendon are released completely from medial to lateral (Figure 9). This is the key maneuver for being able to fully mobilize the extensor mechanism. After completing this, the patella can then be subluxed into the lateral gutter. Creating a large, full-thickness, lateral subcutaneous flap during the initial exposure is necessary in order to create a pocket into which the patella can be subluxed. A 90 degree bent Hohman or Z-retractor is placed in the lateral gutter at the level of the quadriceps tendon insertion to maintain retraction of the patella. Flexing the knee to approximately 90 degrees then provides excellent exposure of the entire joint and the appropriate procedure can be performed (Figure 10). A standard closure is performed at the end of the case (Figure 11). The closure is quite simple as no muscle needs to be repaired.

## DISCUSSION

The medial subvastus approach was originally described in the German literature by Erkes in 1929.<sup>7</sup> A modified version was re-introduced by Hoffman in 1991.<sup>6</sup> A so-called “mini” subvastus approach has since been described.<sup>7,8,11</sup> There are



**Figure 10.** Exposure of articular surfaces. In this example, a medial unicompartmental arthroplasty is being performed. During total knee arthroplasty, we routinely place a gnuiled pin in the patellar tendon insertion to protect it from detachment during the case.



**Figure 11.** Standard closure of the arthrotomy. The VMO is left completely intact.

currently multiple reports in the literature describing the results with respect to total knee arthroplasty. Although concerns have been raised regarding appropriate component positioning, many studies demonstrate more rapid recovery, better pain scores, less blood loss and better short term knee range of motion when comparing the subvastus approach to more traditional approaches.<sup>1-5, 9,12</sup> Recently, Schroer et. al published their results of 600 primary total knee arthroplasties performed through a subvastus approach.<sup>10</sup> Follow-up was short-term, averaging 28 months. A historical group of 150 total knee arthroplasties performed through a standard medial parapatellar arthrotomy was used as a control. Overall, there were eleven major complications (1.8%) requiring reoperation in the subvastus group and six (4.0%) in the traditional group. The rate of both major and minor complications was found to be independent of surgical technique. The rate of major complications in the subvastus group was found to be associated with surgical experience, as the rate was reduced by 16% for each additional fifty procedures performed. Mean knee flexion at one year averaged 125 degrees in the subvastus group and

114 degrees in the traditional group. Average operative time was initially higher in the subvastus group, but decreased with experience so that it was less than the traditional group in the last 400 subvastus procedures performed. Of note, the authors stated that 99% of total knee arthroplasties performed during the study period were done through a subvastus approach with 91% of patients classified as overweight and 11% as morbidly obese.

We have found the subvastus approach to provide excellent exposure and allow quicker advancement of rehabilitation after knee surgery. As with any procedure, there is a definite learn-

ing curve associated with the subvastus approach. The senior author's technique and indications have evolved with time and experience. Less emphasis is placed on the length of the skin incision and more emphasis placed on careful dissection of large medial and lateral skin flaps and atraumatic mobilization of the muscle. In addition to total knee arthroplasty and medial unicompartmental knee arthroplasty, we have applied the subvastus approach to the treatment of other intra-articular pathologies, primarily chondral defects. Procedures such as autologous chondrocyte implantation and osteoarticular autografts can easily be performed through this approach.

## References

1. **Aglietti P, Baldini A, Sensi L.** Quadriceps-sparing versus mini-subvastus approach in total knee arthroplasty. *Clinical Orthopaedics & Related Research.* 452:106-11, 2006 Nov.
2. **Berth A, Urbach D, Neumann W, Awiszus F.** Strength and voluntary activation of quadriceps femoris muscle in total knee arthroplasty with midvastus and subvastus approaches. *Journal of Arthroplasty.* 22(1):83-8, 2007 Jan.
3. **Boerger TO, Aglietti P, Mondanelli N, Sensi L.** Mini-subvastus versus medial parapatellar approach in total knee arthroplasty. *Clinical Orthopaedics & Related Research.* 440:82-7, 2005 Nov.
4. **Chang CH, Chen KH, Yang RS, Liu TK.** Muscle torques in total knee arthroplasty with subvastus and parapatellar approaches. *Clinical Orthopaedics & Related Research.* (398):189-95, 2002 May.
5. **Dalury DF, Dennis DA.** Mini-incision total knee arthroplasty can increase risk of component malalignment. *Clinical Orthopaedics & Related Research.* 440:77-81, 2005 Nov.
6. **Hofmann AA, Plaster RL, Murdock LE.** Subvastus (Southern) approach for primary total knee arthroplasty. *Clinical Orthopaedics & Related Research.* (269):70-7, 1991 Aug.
7. **Masri BA, Kim WY, Pagnano M.** Mini-Subvastus Approach for Minimally Invasive Total Knee Replacement. *Tech Knee Surg* 6(2): 124-130, 2007
8. **Pagnano MW, Meneghini RM.** Minimally invasive total knee arthroplasty with an optimized subvastus approach. *Journal of Arthroplasty.* 21(4 Suppl 1):22-6, 2006 Jun.
9. **Roysam GS, Oakley MJ.** Subvastus approach for total knee arthroplasty: a prospective, randomized, and observer-blinded trial. *Journal of Arthroplasty.* 16(4):454-7, 2001 Jun.
10. **Schroer WC, Diesfeld PJ, Reedy ME, LeMarr AR.** Evaluation of complications associated with six hundred mini-subvastus total knee arthroplasties. *Journal of Bone & Joint Surgery - American Volume.* 89 Suppl 3:76-81, 2007 Oct.
11. **Sporer SM.** The minimally invasive subvastus approach for primary total knee arthroplasty. *The Journal of Knee Surgery.* 19(1):58-62, 2006 Jan.
12. **Weinhardt C, Barisic M, Bergmann EG, Heller KD.** Early results of subvastus versus medial parapatellar approach in primary total knee arthroplasty. *Archives of Orthopaedic & Trauma Surgery.* 124(6):401-3, 2004 Jul.