

REVISION ANTERIOR CRUCIATE LIGAMENT RECONSTRUCTION - DEALING WITH AN ENLARGED TIBIAL TUNNEL

PETER S. VEZERIDIS, MD, BERTRAM ZARINS, MD

DEPARTMENT OF ORTHOPAEDIC SURGERY, MASSACHUSETTS GENERAL HOSPITAL, BOSTON, MA

INTRODUCTION

Reconstructing a torn anterior cruciate ligament (ACL) in a knee that has had prior ACL surgery presents challenges, especially if multiple procedures have been done in the past. Revision ACL surgery will continue to become more common as the number of primary ACL reconstruction procedures continues to increase. A common problem faced by the surgeon in the revision setting is an enlarged tibial tunnel [1, 2]. This problem is most commonly encountered in reconstructions with allograft, hamstring autograft, and synthetic Gore-tex grafts [3-8]. Occasionally, the bone in the proximal tibia is almost hollow after the failed graft and the interference screw have been removed. In this scenario, new interference screw fixation is not possible.

Several techniques can be employed to fix the new bone plug of a bone-tendon-bone graft in an enlarged tibial tunnel. These include 1) staging the revision by first removing the hardware and filling the tunnel with iliac bone graft and delaying the insertion of the new ACL graft until the bone graft incorporates (about a year); 2) nesting more than one interference screw in the tibial tunnel; 3) post-and-washer fixation; and 4) staple fixation [4, 9-11].

We present an alternate method of internal fixation of the plug to the tibia using AO/Synthes 3.5 mm fully threaded cortical screws with a lag technique through the tendon graft. The advantages of this method include the ability to switch to this technique in the midst of an operation without change in exposure, and the ability to secure immediate fixation regardless of the size of the tibial tunnel.

TECHNIQUE

Using an osteotome and rongeur, the anterior cortex of the tibia is removed to expose the anterior part of the bone plug and

to deepen the tunnel into a trough. The graft is pushed into the trough so that it is buried below the anterior surface of the tibia. While applying tension to the graft with the knee in extension, a drill hole is made through the bone plug and underlying tibia. The drill bit is left in place. A second drill hole is made through the plug parallel to the first drill hole. An AO/Synthes 3.5 mm fully threaded cortical screw is then inserted into the second drill hole using a lag technique to create compression across the graft. The first drill bit is then removed and another cortical screw is inserted into the first drill hole. Both screws should obtain purchase in the posterior cortex of the tibia in order to generate compression across the graft. This technique may be employed with or without the use of washers.

This method is difficult to employ if the graft is short and works best if the graft is too long, protruding from the tibial tunnel.

CASE REPORTS

We describe two patients who have undergone revision ACL reconstruction with the currently described technique used for tibial tunnel fixation.

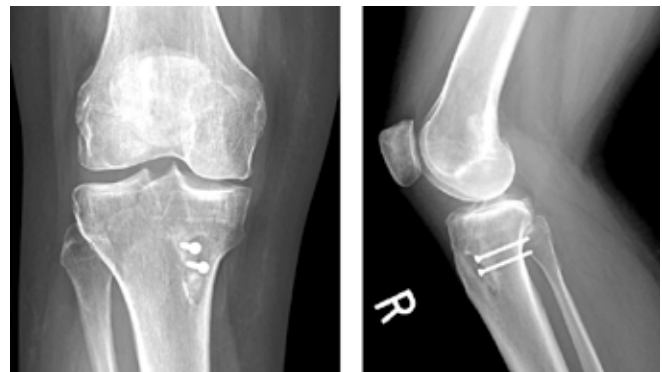


Fig. 1. AP and lateral radiographs 7 months after right knee revision ACL reconstruction using compression screw fixation of the graft within the tibial tunnel.

Peter S. Vezeridis, MD, PGY-3 Resident, Harvard Combined Orthopaedic Residency Program

Bertram Zarins, MD, Augustus Thorndike Clinical Professor of Orthopaedic Surgery, Harvard Medical School, Massachusetts General Hospital, Boston, MA

Address Correspondence to:

Bertram Zarins, MD
Massachusetts General Hospital
Sports Medicine Service
175 Cambridge Street, 4th Floor
Boston, MA 02114

Phone: (617) 726-3421

Fax: (617) 726-3438

Email: bzarins@partners.org

CASE I

The patient is a 49 year-old woman who sustained a right knee injury in July 2007, tearing the ACL. In October 2007 the torn ACL was reconstructed bone-tendon-bone allograft. She re-injured the knee in March 2008 and as a result experienced functional instability of the knee. Examination found 2+ Lachman and pivot shift tests. In July 2008 the patient underwent right knee revision ACL reconstruction using mid-third patella tendon allograft with interference screw fixation of distal femur and compression screw fixation of the proximal tibia as

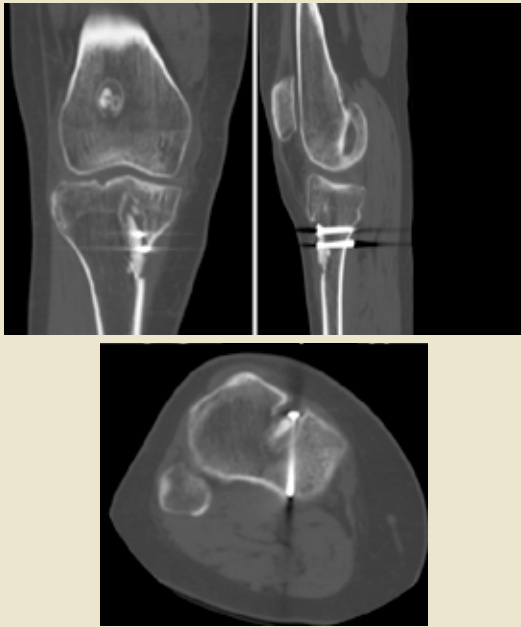

Fig. 2. Coronal, sagittal, and axial CT images 7 months after right knee revision ACL reconstruction using screw fixation of the graft within the tibial tunnel.

described previously. Following this, the knee was stable and had full range of motion with negative Lachman and pivot shift tests. Radiographs and CT images at 7 months postoperatively are shown in Figures 1 and 2, respectively.

CASE 2

The patient is a 35 year-old woman who in 1997 fell while skiing, sustaining a right knee injury and ACL tear. Hamstring tendon graft ACL reconstruction was performed six weeks after the injury. The patient experienced recurrent instability postoperatively and subsequently underwent two arthroscopic partial medial meniscectomies in July 2000 and January 2001. Physical examination revealed a 2+ Lachman test and 1+ pivot shift. In October 2008 the patient underwent right knee anterior cruciate ligament reconstruction using mid-third patella tendon allograft using tibial tunnel compression screw fixation. The knee was tested and found to have negative Lachman and pivot shift tests. Plain radiographs three months postoperatively are shown in Figure 3.

DISCUSSION

Revision ACL reconstruction is indicated in patients with instability and documented laxity [12]. Tunnel enlargement is a challenging problem that is often faced in the revision setting [2]. While the exact etiology of tunnel enlargement is not yet clearly understood, multiple mechanical and biological factors likely contribute to this process [1]. Tunnel enlargement can be classified as cystic, cone, cavity, or linear [3].

With any revision ACL reconstruction, thorough preoperative evaluation is essential. This begins with a detailed history with special attention to the primary procedure, postoperative rehabilitation regimen, return to activities, and onset of recurrent instability. Assessment of symptomatology must differentiate between instability and pain, as pain may be the result of

factors other than instability, and ACL reconstruction may be unsuccessful in resolving pain [4]. Previous operative notes should be obtained when available to provide valuable information for preoperative planning. Knowledge of the type of graft and technique used, pathology identified, and hardware implanted will facilitate the revision procedure.

Physical examination should be systematic. Any signs of infection, including warmth, effusion, and pain with range of motion, should alert the clinician and prompt further investigation. Gait, alignment, crepitus, range of motion, and varus and valgus stability must be documented. Limitations in range of motion must be treated prior to proceeding with revision ACL reconstruction. The authors' examination of laxity includes the Lachman and pivot shift tests. KT-1000 arthrometer testing may be useful in providing objective documentation of laxity of the involved knee [11].

Preoperative imaging of the affected knee includes weight-bearing anteroposterior and 45-degree flexion lateral radiographs. Comparison to previous radiographs should be performed to evaluate for progressive tunnel enlargement [10]. Notch architecture may be a contributing factor to the failure of the primary graft [13]. CT provides information regarding tunnel anatomy if plain radiographs raise suspicion for tunnel osteolysis. MRI can be considered to provide further information about the graft, menisci, articular surfaces, and tunnel location and orientation [10, 14].

Rehabilitation following revision ACL reconstruction varies depending upon several surgical and patient variables [11]. Surgical variables that must be considered include graft type, fixation strength, graft position, and additional surgical fixation of secondary restraints. Activity level, demand, size, and limb alignment are patient variables that must be taken into account when determining the rehabilitation regimen [11].

The outcomes of revision ACL reconstruction are not as favorable as primary ACL reconstruction, and thus patients should be counseled regarding realistic expectations after revision [11]. Results of a prospective case-control study of 49 patients undergoing two-stage ACL revision with bone grafting of the tibial tunnel found that this revision technique can achieve laxity measurements similar to those after primary ACL

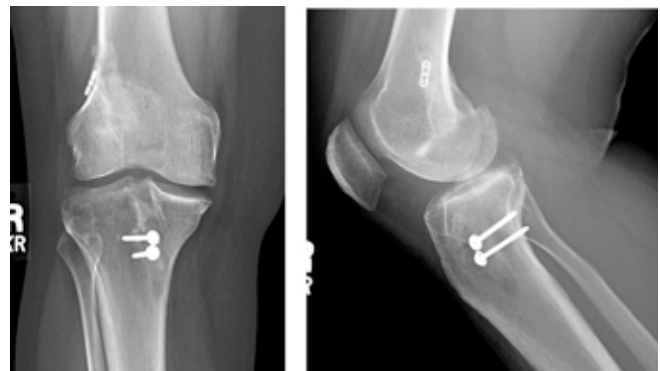

Fig. 3. AP and lateral radiographs 3 months after right knee revision ACL reconstruction using screw fixation of the graft within the tibial tunnel. Washers can be used in order to increase the surface area for compression across the graft, as demonstrated in these radiographs.

reconstruction although International Knee Documentation Committee scores were lower [9]. However, as techniques improve results after revision procedures should begin to approach the results of primary surgery. A recent case series

of 60 patients evaluated at mean 41 month follow-up after revision ACL reconstruction demonstrated results that were mildly less satisfactory compared to the results of other case series of primary reconstruction [15].

References

- [1] **Wilson TC, Kantaras A, Atay A, and Johnson DL**, Tunnel enlargement after anterior cruciate ligament surgery, *Am J Sports Med* 2004; 32: 543-549.
- [2] **Jaureguito JW, and Paulos LE**, Why grafts fail, *Clin Orthop Relat Res* 1996; 25-41.
- [3] **Clatworthy MG, Annear P, Bulow JU, and Bartlett RJ**, Tunnel widening in anterior cruciate ligament reconstruction: a prospective evaluation of hamstring and patella tendon grafts, *Knee Surg Sports Traumatol Arthrosc* 1999; 7: 138-145.
- [4] **Getelman MH, and Friedman MJ**, Revision anterior cruciate ligament reconstruction surgery, *J Am Acad Orthop Surg* 1999; 7: 189-198.
- [5] **L'Insalata JC, Klatt B, Fu FH, and Harner CD**, Tunnel expansion following anterior cruciate ligament reconstruction: a comparison of hamstring and patellar tendon autografts, *Knee Surg Sports Traumatol Arthrosc* 1997; 5: 234-238.
- [6] **Steadman JR, Seemann MD, and Hutton KS**, Revision ligament reconstruction of failed prosthetic anterior cruciate ligaments, *Instr Course Lect* 1995; 44: 417-429.
- [7] **Jansson KA, Harilainen A, Sandelin J, Karjalainen PT, Aronen HJ, and Tallroth K**, Bone tunnel enlargement after anterior cruciate ligament reconstruction with the hamstring autograft and endobutton fixation technique. A clinical, radiographic and magnetic resonance imaging study with 2 years follow-up, *Knee Surg Sports Traumatol Arthrosc* 1999; 7: 290-295.
- [8] **Webster KE, Feller JA, and Hameister KA**, Bone tunnel enlargement following anterior cruciate ligament reconstruction: a randomised comparison of hamstring and patellar tendon grafts with 2-year follow-up, *Knee Surg Sports Traumatol Arthrosc* 2001; 9: 86-91.
- [9] **Thomas NP, Kankate R, Wandless F, and Pandit H**, Revision anterior cruciate ligament reconstruction using a 2-stage technique with bone grafting of the tibial tunnel, *Am J Sports Med* 2005; 33: 1701-1709.
- [10] **Noyes FR, Barber-Westin SD, and Roberts CS**, Use of allografts after failed treatment of rupture of the anterior cruciate ligament, *J Bone Joint Surg Am* 1994; 76: 1019-1031.
- [11] **Safran MR, and Harner CD**, Technical considerations of revision anterior cruciate ligament surgery, *Clin Orthop Relat Res* 1996; 50-64.
- [12] **George MS, Dunn WR, and Spindler KP**, Current concepts review: revision anterior cruciate ligament reconstruction, *Am J Sports Med* 2006; 34: 2026-2037.
- [13] **Houseworth SW, Mauro VJ, Mellon BA, and Kieffer DA**, The intercondylar notch in acute tears of the anterior cruciate ligament: a computer graphics study, *Am J Sports Med* 1987; 15: 221-224.
- [14] **Vellet AD, Marks PH, Fowler PJ, and Munro TG**, Occult posttraumatic osteochondral lesions of the knee: prevalence, classification, and short-term sequelae evaluated with MR imaging, *Radiology* 1991; 178: 271-276.
- [15] **Denti M, Lo Vetere D, Bait C, Schonhuber H, Melegati G, and Volpi P**, Revision anterior cruciate ligament reconstruction: causes of failure, surgical technique, and clinical results, *Am J Sports Med* 2008; 36: 1896-1902.