Revision Anterior Cruciate Ligament Reconstruction: Preoperative Planning and Technical Considerations

Amon T. Ferry, MD, Samuel K. Van de Velde, MD, Guoan Li, PhD, Peter Asnis, MD, Bertram Zarins, MD, Thomas J. Gill, MD

Massachusetts General Hospital

ABSTRACT

Revision anterior cruciate ligament (ACL) reconstruction poses a challenging situation for the surgeon. First and foremost, a diagnosis as to why the index reconstruction failed must be made – was this simply the result of a new trauma, or were there technical, diagnostic, or biological considerations associated with the index surgery that predisposed it to failure. From a surgical standpoint, a successful revision requires selection of an appropriate graft, a detailed surgical plan with regards to tunnel management, graft fixation, and treatment of associated injuries, as well as postoperative rehabilitation. This presentation is meant to concentrate on the technical aspects of revision ACL surgery. We detail our approach to revising a failed primary ACL reconstruction and discuss several of the technical challenges faced in the revision setting.

INTRODUCTION

It has been estimated that more than 100,000 anterior cruciate ligament (ACL) injuries occur annually in the United States with over half of these patients opting for surgical reconstruction. The goals of surgery are a stable knee with full painless motion that can withstand the stresses of sporting activities and prevent further damage to other intra-articular structures. Good to excellent subjective results following primary ACL reconstruction can be expected in the majority of patients, and more than half will return to their pre-injury level of athletic participation[2, 6]. Even with good to excellent subjective outcomes, previous biomechanical studies suggest that ACL reconstruction does not restore normal in vivo kinematics or forces across the ACL graft[7, 9]. Those patients that return to high-risk activities, such as sports that involve rapid deceleration and cutting maneuvers (football, basketball, soccer, and skiing), will be at higher risk for failure. As the number of primary ACL reconstructions increases, naturally so does the number of failures and thus the necessity for revision procedures.

When compared to primary ACL reconstruction, an inferior outcome can often be expected with a revision procedure. Clinical failures have been noted to occur in up to 35% of patients[4, 5, 8] with return to pre-injury level of activity being as low as 54% of patients[11]. Even though the clinical results are often inferior, there is considerable evidence to suggest that knee stability comparable to a primary reconstruction can be achieved in the revision setting[1, 3, 10, 12]. To achieve optimum results though, well-executed preoperative planning and surgical technique are critical. In this article, we detail our preferred treatment plan and discuss the technical considerations of revision surgery.

PREOPERATIVE PLANNING

When approaching a revision ACL reconstruction, it is especially important to create a detailed surgical plan. First, anatomic factors that might affect the outcome of the revision should be assessed. This includes the mechanical axis, associated ligamentous instabilities if any, and associated meniscus or articular cartilage damage. From a technical perspective, the operative plan should address "tunnel management," which type of graft should be used, as well as the method of fixation. Tunnel management should include an assessment of the position and quality of the tibial and femoral tunnels as well as noting any osteolysis or presence of hardware. The preoperative work-up should include preoperative standing radiographs (Figure 1) and the previous operative note. Preoperative radiographs are useful to assess for tunnel position and widening.

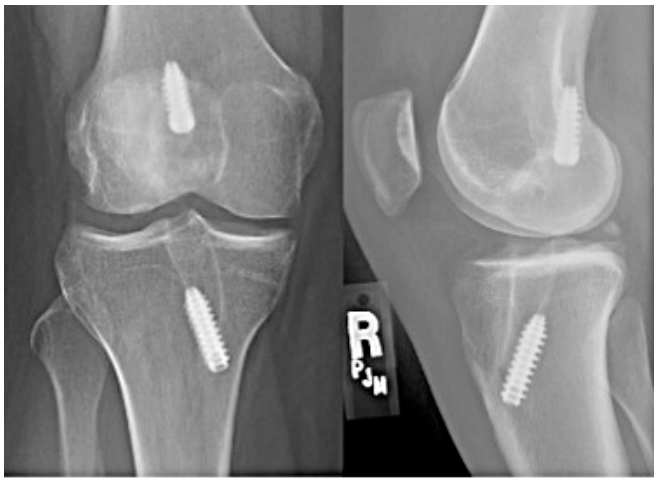

Figure 1: AP and Lateral radiographs illustrating the tunnel position and interference screw fixation

Sports Medicine Service
Massachusetts General Hospital / Harvard Medical School
175 Cambridge St.
Boston, MA 02114

Please direct correspondence and reprint requests to:

Thomas J. Gill, MD

Figure 2: Sagittal MRI image showing tibial tunnel and torn ACL graft

Figure 3: AP radiograph showing femoral tunnel osteolysis

The previous operative note provides valuable information such as what type of reconstruction was performed (single vs. double bundle), the type of graft used (i.e. autograft, allograft, hamstring, BPTB, or achilles), the technique used to drill the femoral tunnel (i.e. endoscopic, two-incision, or anteromedial portal), what type of fixation was used, what concomitant procedures were performed, and if there were any complications. For instance, if a posterior cortical blow-out was noted during the primary procedure, this will affect the surgical plan and must be known pre-operatively. If hardware could be encountered during the revision, then the appropriate instruments should be requested. An MRI (Figure 2) is often useful to document the failed graft and identify any concomitant intra-articular injuries. However, the decision to perform a revision reconstruction is based more on the presence or absence of a pivot shift, since it is not uncommon for an MRI to show an "intact" primary allograft reconstruction, but the ligament has become stretched or is so lax that the knee is functionally unstable. Cross-sectional imaging with CT scan or MRI can also be helpful when evaluating tunnel position or when tunnel widening is identified on plain radiographs.

Anticipation of tunnel management is fundamental to the revision surgery. If the previous tunnels are well positioned and no osteolysis is noted, these tunnels may be reused. This is rare. Most commonly, malpositioned tunnels can often be bypassed entirely during the revision procedure. For example, the commonly encountered vertical femoral tunnel is often a result of a more sagittally oriented tibial tunnel. During the revision procedure, we try to correct any tunnel positioning, since this is often a predisposing cause of the index graft failure. In order to place the femoral tunnel more anatomically, the tibial guide should be rotated medially so that a new, more oblique, tunnel is created. This new tibial tunnel often allows the previous femoral tunnel to be completely avoided using the endoscopic single-incision technique. If such positioning will overlap with the previous tunnel, we will often perform an acute grafting technique using allograft cylindrical bone plugs or biocomposite screws first. This will allow the revision tunnel to be drilled without concern for collapse into the index tunnel. If a previous metal screw can be avoided with the new tunnel, it is best left in place.

If, however, the tunnels are in appropriate position and tunnel osteolysis will be encountered during reaming (Figure 3), then special consideration must be made. Divergent tunnels with an intact bony tube can be created by different methods depending on the placement of the original tunnels and the method of initial reconstruction. For example, if a primary reconstruction if performed using an endoscopic technique with an appropriate tibial tunnel and significant femoral osteolysis, then a two-incision technique or reaming from the anteromedial portal will likely allow for the creation of a femoral tunnel with adequate bone stock for fixation. The opposite holds true when a two-incision or anteromedial portal technique was used to ream the femoral tunnel during the primary reconstruction. When severe osteolysis is encountered, this may require a staged reconstruction with a bone-grafting procedure first followed by ACL reconstruction in 6-12 months later. This case has been extremely rare in our practice.

Graft selection begins with the decision to use autograft or allograft. The advantages of autograft tissue are the same for the revision as for the primary reconstruction: decreased incorporation time, less chance of biological rejection, and a decreased risk of disease transmission. We also believe that it is a biomechanically superior graft. The theoretical advantages of using allograft tissue are the lack of donor site morbidity, decreased post-operative pain, decreased operative time, and the ability to customize the bone blocks.

The graft selected for use in the revision setting should be tailored to the individual patient. The use of allograft tissue allows larger bone plugs to be fashioned in order to accommodate tunnel widening that may be encountered during revision surgery. Ultimately, the type of fixation is largely predicated on the type of graft used. Interference screw fixation has been shown to provide the strongest initial graft fixation and is our method of choice. Previous studies have shown no functional difference in outcome following revision ACL reconstruction using either allograft or autograft tissues[1, 11]. Additionally, Ahn et al reported their results of revision ACL using hamstring autograft, BPTB allograft, or achilles tendon allograft and found no difference suggesting that the success of the revision surgery does not depend on the graft used[1]. In our experience, however, the largest group of revision surgeries occur in young athletic patients who were initially treated with an allograft reconstruction, especially using allografts such as tibialis anterior tendons.

Finally, preoperative patient education is extremely important prior to a revision procedure and the expectations of the patient should be modified. Revision ACL surgery represents a salvage procedure and the patient should be counseled appropriately that the outcomes are not likely to be as good as a primary procedure and that the goal of surgery is to provide a stable pain-free knee. Return to sport is the goal, but is less predictable. In many cases, the status of the articular cartilage and meniscus are major factors in the return to sports.

SURGICAL TECHNIQUE

Our graft of choice for revision ACL reconstruction is the BPTB allograft. For those patients that were primarily reconstructed with a hamstring autograft or any allograft tissue, however, we will consider using a BPTB autograft. Achilles tendon, quadriceps tendon, and soft tissue grafts, are seldom used in our practice for revision ACL procedures. We prefer the BPTB allograft for many of the reasons cited previously. In particular, the BPTB allograft is a stiffer graft with a shorter functional length, has decreased morbidity and the ability to customize the bone plugs and obtain rigid initial fixation with interference screws are attractive.

We perform the majority of our ACL reconstructions under general anesthesia and will typically supplement with femoral nerve blocks based on surgeon and patient preference. Once the patient is anesthetized, Lachman and pivot-shift exams are performed in order to confirm ACL deficiency, and rule out associated instability patterns. While anesthetized, we routinely examine the medial collateral ligament (MCL), lateral collateral ligament (LCL), and the posterior cruciate ligament (PCL) to ensure adequate stability of these ligaments. The allograft, if used, is then thawed in saline at room temperature and prepared in a similar fashion to that of a primary procedure. Final sizing of the bone plugs may be delayed, however, if tunnel osteolysis is anticipated so that larger plugs may be fashioned to accommodate an enlarged tunnel.

Standard arthroscopic portals are created and routine diagnostic arthroscopy is then performed. Any meniscal pathology is addressed at this time. Debridement of the residual graft is performed. A notchplasty is performed if the width of the notch is less than 15mm, and the intra-articular position of the tibial and femoral tunnels is assessed. If a femoral interference screw was thought to interfere with the drilling of the revision tunnel, then it should be removed at this time (Figure 4). It has been our experience that a well-fixed bone composite screw can be reamed without difficulty and rarely poses a problem when preparing a revision tunnel. If, however, metal or poly –L lactic acid (PLLA) screws are used for primary fixation we often remove the screw and replace them with a bone composite screw in an effort to avoid falling into a defect left from the previous interference screw. We have found that these biocomposite screws will incorporate with the surrounding bone, thus acting in a similar manner as a bone graft. Regardless of the technique used, it is essential to restore any bone loss present.

We prefer the endoscopic single-incision technique, when possible. Therefore, with patients where either a two-incision or anteromedial portal was previously used to drill the femoral tunnel, our femoral tunnel is typically in a unique position. A graft initially placed in a vertical position with an appropriate tibial insertion site can often be revised by maintaining the same intraarticular position but rotating the tibial aimer so that the starting point is more medial on the tibia, approximately half-way between the tibial tubercle and the posteromedial border of the tibia. The goal of using the trans-tibial tunnel technique for drilling the femoral tunnel in this fashion is not only to avoid the previous tunnel, but place it in a more isometric position closer to the anatomic footprint. If the tibial tunnel is to be re-used, then the previous screw is identified, removed and replaced with a bone-composite screw.

Figure 4: Arthroscopic view of femoral interference screw removal

Figure 5: AP radiograph showing allograft bone grafting to tibial tunnel

Figure 6: AP and lateral radiograph showing the revision fixation

We place the intra-articular position of the tibial tunnel in the location of the native footprint, along the down-slope of the medial tibial spine at the level of the posterior border of the anterior horn lateral meniscus. This typically corresponds to a position approximately 8mm anterior to the tibial insertion of the PCL. We prefer to place the femoral tunnel in the 10-10:30 or the 1:30-2 position on the clock face, for the right and left knees respectively. In order to obtain this position with a trans-tibial technique, we pay close attention to the obliquity of the tibial tunnel in both the sagittal and coronal plane. In the coronal plane, the tibial aimer should be rotated to target the desired position on the clock-face. In the sagittal plane we raise the tibial aimer to a position that is parallel with the tibial plateau. The guide wire is then placed and the tibial tunnel is reamed. If a previous tunnel or interference screw prevents the initial use of a 10 or 11 mm reamer, then appropriate tunnel positioning can be achieved with sequential reaming, starting with a 6mm reamer. Additional soft tissue and bone debris is removed from the knee and the femoral over-the–top guide is inserted into the knee through the tibial tunnel. We typically use a 6mm offset aimer to ensure

a 1mm posterior cortex for a 10mm tunnel. This may need to be adjusted if significant tunnel osteolysis is encountered, or a larger bone block is used. In the case of a significant tunnel osteolysis or a posterior cortical blow-out, we prefer to switch to a 2-incision technique to ensure an intact tube for the femoral tunnel.

Tunnel widening may be encountered during a revision procedure and it is important to have identified this possibility pre-operatively and to devise a plan for tunnel management. If the primary screws were replaced with biocomposite screws earlier in the revision and the biocomposite screw was encountered during reaming, then the tract for the new interference screw should be pre-tapped prior to insertion. If a significant bony void exists then stacked biocomposite screws or strips of allograft bone (Figure 5) can be used. These techniques have proved adequate in providing acceptable initial fixation of the graft in the vast majority of revision cases we have performed. Final fixation is gained using interference screws with the knee in full extension and approximately 20-lb of tension on the graft (Figure 6).

CONCLUSION

The management of patient with a failed ACL reconstruction can be very challenging. Non-anatomic tunnels are often encountered and should not be re-used. BPTB is typically our graft of choice and tunnel widening may need to be addressed with either allograft or bone substitute. Adequate fixation can typically be achieved using an interference screw, but additional tibial fixation may be required. Surgeons performing ACL revision surgery should be facile with both the two-incision technique and endoscopic technique, as well as be familiar with the use of multiple graft options.

References

1. **Ahn JH, Lee YS, Ha HC.** Comparison of revision surgery with primary anterior cruciate ligament reconstruction and outcome of revision surgery between different graft materials. *Am J Sports Med.* Oct 2008;36:1889-1895.
2. **Bach BR, Jr**. Revision anterior cruciate ligament surgery. *Arthroscopy.* Dec 2003;19 Suppl 1:14-29.
3. **Denti M, Lo Vetere D, Bait C, Schonhuber H, Melegati G, Volpi P.** Revision anterior cruciate ligament reconstruction: causes of failure, surgical technique, and clinical results. *Am J Sports Med.* Oct 2008;36:1896-1902.
4. **Fox JA, Pierce M, Bojchuk J, Hayden J, Bush-Joseph CA, Bach BR, Jr.** Revision anterior cruciate ligament reconstruction with nonirradiated fresh-frozen patellar tendon allograft. *Arthroscopy.* Oct 2004;20:787-794.
5. **Grossman MG, ElAttrache NS, Shields CL, Glousman RE.** Revision anterior cruciate ligament reconstruction: three- to nine-year follow-up. *Arthroscopy.* Apr 2005;21:418-423.
6. **Lewis PB, Parameswaran AD, Rue JP, Bach BR, Jr.** Systematic review of single-bundle anterior cruciate ligament reconstruction outcomes: a baseline assessment for consideration of double-bundle techniques. *Am J Sports Med.* Oct 2008;36:2028-2036.
7. **Li G, Papannagari R, DeFrate LE, Yoo JD, Park SE, Gill TJ.** Comparison of the ACL and ACL graft forces before and after ACL reconstruction: an in-vitro robotic investigation. *Acta Orthop.* Apr 2006;77:267-274.
8. **Noyes FR, Barber-Westin SD, Roberts CS.** Use of allografts after failed treatment of rupture of the anterior cruciate ligament. *J Bone Joint Surg Am.* Jul 1994;76:1019-1031.
9. **Papannagari R, Gill TJ, Defrate LE, Moses JM, Petruska AJ, Li G.** In vivo kinematics of the knee after anterior cruciate ligament reconstruction: a clinical and functional evaluation. *Am J Sports Med.* Dec 2006;34:2006-2012.
10. **Thomas NP, Kankate R, Wandless F, Pandit H.** Revision anterior cruciate ligament reconstruction using a 2-stage technique with bone grafting of the tibial tunnel. *Am J Sports Med.* Nov 2005;33:1701-1709.
11. **Uribe JW, Hechtman KS, Zvijac JE, Tjin ATEW.** Revision anterior cruciate ligament surgery: experience from Miami. *Clin Orthop Relat Res.* Apr 1996:91-99.
12. **Weiler A, Schmeling A, Stohr I, Kaab MJ, Wagner M.** Primary versus single-stage revision anterior cruciate ligament reconstruction using autologous hamstring tendon grafts: a prospective matched-group analysis. *Am J Sports Med.* Oct 2007;35:1643-1652.