Talar Neck Fracture after Tibiotalar Arthrodesis: A Case Report

[1]John Y. Kwon, MD, [2]Mark S. Myerson, MD
[1]Massachusetts General Hospital, [2]The Institute for Foot & Ankle Reconstruction at Mercy

ABSTRACT

Fractures of the talar neck are uncommon and typically follow high energy trauma. Displaced fractures associated with peritalar dislocations have been shown to have poor outcomes with high complication rates.[1-13] We report an unusual case of a patient who underwent successful ankle arthrodesis who then sustained a low energy trauma resulting in a displaced talar neck fracture. She went on to have open reduction internal fixation with subsequent healing. To our knowledge there has been no previous report of this in the literature. Although likely a rare occurrence we feel that this association may be underreported. We use this case to highlight issues regarding surgical technique when performing ankle arthrodesis and how screw placement may predispose patients to talar neck fractures. In addition we discuss considerations & techniques for internal fixation of a talar neck fracture after ankle arthrodesis. Finally we discuss how this case report may highlight current thoughts regarding the pathomechanics of talar neck fractures.

INTRODUCTION

Ankle arthrodesis is a commonly performed procedure for end stage arthritis of the tibiotalar joint. Many techniques have been described to achieve arthrodesis including external fixation as well as internal fixation using various instrumentation from intramedullary nails, screws to plate fixation.[14-25] We find ankle fusion performed using a mini-arthrotomy approach with three cross screw fixation to be effective. We have found this technique to be reliable, adequate to correct more significant deformity and to allow for rapid bone healing due to little periosteal stripping and soft tissue dissection.

Fractures of the talar neck are generally a result of high energy trauma. Many authors have theorized that talar neck fractures result from a forced hyperdorsiflexion of the foot forcing the talar neck against the anterior tibial plafond. However, Peterson and Romanus in a cadaver study were unable to produce talar neck fractures using this mechanism and instead were able to successfully reproduce talar neck fractures only with the ankle in neutral position and ankle motion eliminated.[26]

CASE REPORT

The patient is a healthy 61 year old female who initially presented in July 2009 with left ankle pain. She had a history significant for multiple ankle sprains and reported increasing ankle pain and disability. She was able to ambulate but had significant difficulties with activities of daily living. She was found to have tibiotalar arthrosis with varus malpositioning and had failed conservative treatment. Surgical options were discussed including ankle replacement, distal tibial osteotomy and ankle fusion. The patient was eventually taken to the

Figure 1 A
(AP radiograph of the ankle demonstrating tibiotalar arthrosis and varus deformity)

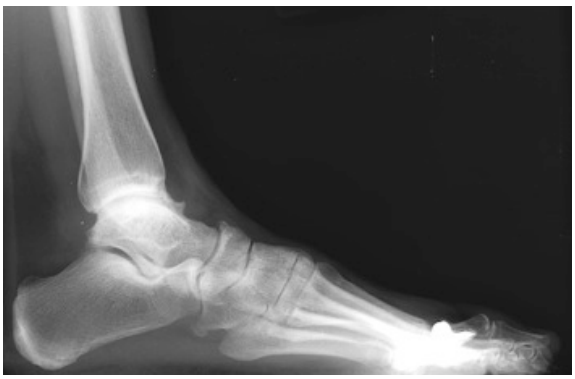

Figure 1B
(Lateral radiograph of the ankle showing tibiotalar arthrosis)

Corresponding author:

John Y. Kwon, MD
Department of Orthopaedic Surgery
Clinical Instructor, Harvard Medical School
Massachusetts General Hospital
Boston, MA 02114

Mark S. Myerson, MD
Director, The Institute for Foot & Ankle Reconstruction at Mercy
301 St. Paul Place
Baltimore, MD 21202

operating theatre in September 2009 where she underwent left tibiotalar arthrodesis. (Figure 1A & 1B) This procedure was performed using a miniarthrotomy approach with a small anterior medial and anterior lateral incision. The joint was debrided of any remaining articular cartilage and prepared in standard fashion. After reduction was obtained the tibiotalar joint was fused using two 6.5 mm and one 5.0 mm partially threaded cancellous screws. The two 6.5 mm screws were placed from the medial distal tibia into the talus while the 5.0mm screw was placed from the lateral fibula medially into the talar body. Post-operatively the patient was placed in a splint and made non-weight bearing.

She was initially seen on POD#10 where she had her splint removed and was found to be doing well. Her staples were left in place and she was placed in an aircast boot with continued non-weightbearing with repeat follow-up in ten days. At the following visit, the patient reported increased pain subsequent to a fall the previous day. She recalls axially loading the extremity while wearing her boot. Radiographs as well as live fluoroscopy demonstrated an unstable displaced fracture of the talus at the neck/body junction. (Fig. 2)

The patient returned to the operating theatre several days later and underwent open reduction internal fixation of the talar neck fracture. We initially attempted percutaneous screw placement using the standard posterior lateral approach under fluoroscopy. However, we experienced significant difficulties in passing the guidewire from the posterior talus into the distal neck due to the previously placed arthrodesis screws. After multiple attempts we abandoned this approach in favor of placing a guidewire in retrograde fashion from the distal talar neck into the talar body. (Fig. 3) Using standard technique an appropriately sized 5.0 mm partially threaded cancellous screw was placed. Several more attempts were made to pass a second guidewire and screw across the talar neck but we were unsuccessful. Due to concerns of inadequate fixation and malunion the decision was made to place additional fixation along the lateral talar neck We felt that this would not only provide additional stability to our construct but would help avoid further devitalizing the talus by avoiding the medial blood supply. An anterior lateral approach to the talar neck was performed. The talar neck was exposed and the fracture was identified. A DePuy small fragment Y plate (DePuy Orthopaedics, Inc. Warsaw, IN) was trialed and contoured and applied in compression along the lateral talar neck using a combination of locking and non-locking screws. (Figure 4) The wounds were thoroughly irrigated and closed in standard fashion. The patient was placed in a splint post-operatively.

Postoperatively the patient did well. She was placed in a short leg cast and remained non-weightbearing for 6 weeks. She was gradually allowed to heel weight bear and was transitioned into an aircast boot at 8 weeks post-operatively. Serial radiographs showed interval healing not only of the talar neck fracture but consolidation of the ankle arthrodesis. A CT scan was performed approximately 12 weeks post-operatively confirming the x-ray findings (Figure 5: Postoperative lateral radiograph,Figure 6 A: Postoperative saggital CT scan showing healed talus fracture, Figure 6 B: Postoperative axial CT scan showing healed talus fracture). The patient is currently doing well and fully weightbearing in a good supportive sneaker.

Figure 2 (Postoperative lateral radiograph demonstrating fracture of the talus at the neck/body junction)

Figure 3 (Intraoperative fluoroscopy showing passing of the guide-wire)

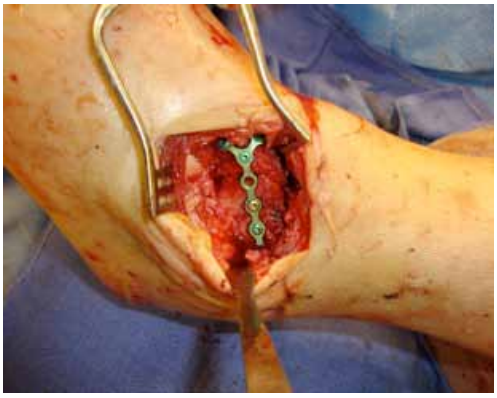

Figure 4 (Intraoperative clinical picture demonstrating placement of internal fixation on the lateral talar neck)

Figure 5 (Postoperative lateral radiograph)

DISCUSSION

To our knowledge talar neck fracture after ankle arthrodesis has not been previously reported in the literature. Although likely rare we feel that this association may be underreported and we report the case of our patient to illustrate several issues

Figure 6 A (Postoperative saggital CT scan showing healed talus fracture)

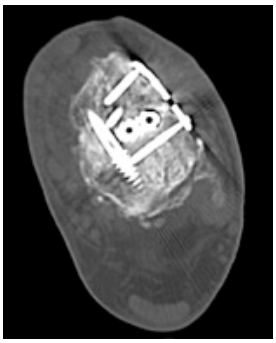

Figure 6 B (Postoperative axial CT scan showing healed talus fracture)

not only regarding the fixation of these fractures but techniques in ankle arthrodesis to prevent this complication.

We have found that tibiotalar arthrodesis using a three cross screw configuration to be successful with high fusion rates. The ideal configuration involves placement of the first screw, the posterior axial screw, from the posterior tibia into the anteromedial talar neck. The second screw is introduced from the medial aspect of the medial malleolus and extending inferolaterally into the lateral body of the talus. Finally the third screw is introduced either from the anterolateral distal tibia or through the fibula. In the case of our patient the ideal configuration was not achieved. The first screw was placed too anteriorly on the distal tibia and did not extend distal into the talar neck. The other two screws were placed in standard fashion. In retrospect this screw configuration likely created a significant stress riser at the talar neck/body junction. In combination with post-operative disuse osteopenia resulting from non-weightbearing status this likely resulted in fracture at this stress riser from a low energy mechanism. We hypothesize that placement of the posterior axial screw down the talar neck decreases the potential stress riser that may result if all three screws terminate in the same location.

Fixation of talar neck fractures after tibiotalar arthrodesis presents a unique difficulty as we experienced. As the patient was only 2.5 weeks postoperative from the ankle fusion when sustaining the talar neck fracture we were unable to remove her previously placed screws to facilitate placement of our talar neck screws. We experienced significant difficulties placing guidewires past these screws and although we were able to place a single axial screw we resorted to supplementing our fixation with a lateral plate construct. Therefore we recommend removal of any previously placed hardware prior to attempted talar neck fixation if adequate fusion of the tibiotalar joint is demonstrated and if previous fixation will impeded fixation of the talar neck. A pre-operative CT scan may be valuable to assess the fracture pattern as well as consolidation of the tibiotalar arthrodesis.

Finally this case report illustrates the controversy regarding the mechanism of talar neck fractures. Many authors have theorized that talar neck fractures result from a forced hyperdorsiflexion of the foot forcing the talar neck against the anterior tibial plafond. This has been based on anecdotal evidence, as well clinical and radiographic observation. Daniels and Smith decribed direct hits, extreme dorsally direct force and supination with the talar neck striking the medial malleolus as mechanisms of talar neck fractures.[27] Peterson and Romanus in a cadaver study were unable to produce talar neck fractures using this mechanism in 20 fresh cadavers.[26] Instead they were able to successfully reproduce talar neck fractures only with the ankle in neutral position and after eliminating ankle motion by compressing the calcaneus against the overlying talus and tibia. With ankle arthrodesis the talus is similarly positioned and constrained. The resulting dorsal force from an axial load through the calcaneus likely produced the talar neck fracture in our patient consistent with Peterson's findings using a cadaver model. Suboptimal screw placement, the creation of a stress riser and post-operative disuse osteopenia likely contributed to this fracture.

This case report illustrates a previously unreported problem. We feel that this association may be underreported with several factors making talar neck fracture after ankle arthrodesis more likely following low energy trauma. We hope that our case report sheds light on this association and offers surgeons insight into treating this difficult problem.

References

1. **Elgafy H, Ebraheim NA, Tile M, Stephen D, Kase J.** Fractures of the talus: experience of two level 1 trauma centers. *Foot Ankle Int.*2000; 21:1023-9.
2. **Frawley PA, Hart JA, Young DA.** Treatment outcome of major fractures of the talus. *Foot Ankle Int.* 1995;16(6):339-45.
3. **Inokuchi S, Ogawa K, Usami N, Hashimoto T.** Long-term follow up of talus fractures. *Orthopedics.*1996 May; 19:477 -81.
4. **Canale ST.** Fractures of the neck of the talus. *Orthopedics.*1990 Oct; 13:1105 -15.
5. **Canale ST, Kelly FB Jr.** Fractures of the neck of the talus. Long-term evaluation of seventy-one cases. *J Bone Joint Surg Am.*1978 Mar; 60:143 -56.
6. **Kenwright J, Taylor RG.** Major injuries of the talus. *J Bone Joint Surg Br.*1970 Feb; 52(1):36 -48.
7. **Schulze W, Richter J, Russe O, Ingelfinger P, Muhr G.** Surgical treatment of talus fractures: a retrospective study of 80 cases followed for 1-15 years. *Acta Orthop Scand.* 2002 Jun;73(3):344 -51.
8. **Szyszkowitz R, Reschauer R, Seggl W.** Eighty-five talus fractures treated by ORIF with five to eight years of follow-up study of 69 patients. *Clin Orthop Relat Res.*1985 Oct; (199):97 -107.
9. **Coltart WD.** Aviator's astragalus. *J Bone Joint Surg Br.*1952; 34:545 -66.
10. **Grob D, Simpson LA, Weber BG, Bray T.** Operative treatment of displaced talus fractures. *Clin Orthop Relat Res.* 1985 Oct;(199):88 -96.
11. **Kleiger B.** Fractures of the talus. *J Bone Joint Surg Am.*1948 Jul; 30A(3):735 -44.
12. **Pennal GF.** Fractures of the talus. *Clin Orthop Relat Res.* 1963; 30:53 -63.
13. **Gilquist J, Oretop N, Stenstrom A, Rieger A, Wennberg E.** Late results after vertical fracture of the talus. *Injury.* 1974 Nov;6(2):173 -9.
14. **Lee AT, Sundberg EB, Lindsey DP, Harris AH, Chou LB.** Biomechanical comparison of blade plate and intramedullary nail fixation for tibiocalcaneal arthrodesis. *Foot Ankle Int.* 2010 Feb;31(2):164-71.
15. **Yakacki CM, Khalil HF, Dixon SA, Gall K, Pacaccio DJ.** Compression forces of internal and external ankle fixation devices with simulated bone resorption. *Foot Ankle Int.* 2010 Jan;31(1):76-85.
16. **Thiryayi WA, Naqui Z, Khan SA.** Use of the Taylor Spatial Frame in Compression Arthrodesis of the Ankle: A Study of 10 Cases. *J Foot Ankle Surg.* 2009 Dec 2. [Epub ahead of print]
17. **Takenouchi K, Morishita M, Saitoh K, Wauke K, Takahashi H, Nagashima M.** Long-term results of ankle arthrodesis using an intramedullary nail with fins in patients with rheumatoid arthritis hindfoot deformity. *J Nippon Med Sch.* 2009 Oct;76(5):240-6.
18. **Zwipp H, Rammelt S, Endres T, Heineck J.** High Union Rates and Function Scores at Midterm Followup With Ankle Arthrodesis Using a Four Screw Technique. *Clin Orthop Relat Res.* 2009 Sep 10. [Epub ahead of print]
19. **Mohamedean A, Said HG, El-Sharkawi M, El-Adly W, Said GZ.** Technique and short-term results of ankle arthrodesis using anterior plating. *Int Orthop.* 2009 Sep 19. [Epub ahead of print]
20. **Niikura T, Miwa M, Sakai Y, Lee SY, Oe K, Iwakura T, Koh A, Koga T, Kurosaka M.** Ankle arthrodesis using antegrade intramedullary nail for salvage of nonreconstructable tibial pilon fractures. *Orthopedics.* 2009 Aug;32(8). pii: orthosupersite.com/view.asp?rID=41937. doi: 10.3928/01477447-20090624-26.
21. **Plaass C, Knupp M, Barg A, Hintermann B.** Anterior double plating for rigid fixation of isolated tibiotalar arthrodesis. *Foot Ankle Int.* 2009 Jul;30(7):631-9.
22. **Verhulst FV, Swierstra BA.** Revision arthrodesis of the ankle: posterior inlay bone grafting in 11 patients. *Acta Orthop.* 2009 Apr;80(2):256-8.
23. **Bowers CA, Catanzariti AR, Mendicino RW.** Traditional ankle arthrodesis for the treatment of ankle arthritis. *Clin Podiatr Med Surg.* 2009 Apr;26(2):259-71.
24. **Gentchos CE, Bohay DR, Anderson JG.** Technique tip: a simple method for ankle arthrodesis using solid screws. *Foot Ankle Int.* 2009 Apr;30(4):380-3.
25. **Ogut T, Glisson RR, Chuckpaiwong B, Le IL, Easley ME.** External ring fixation versus screw fixation for ankle arthrodesis: a biomechanical comparison. *Foot Ankle Int.* 2009 Apr;30(4):353-60.
26. **Peterson L, Romanus B, Dahlberg E.** Fracture of the collum tali—an experimental study. *J Biomech.* 1976;9(4):277-9.
27. **Daniels TR, Smith JW.** Talar neck fractures. *Foot Ankle.* 1993 May;14(4):225-34. Review.