Functional Cement Spacer for Nonsalvageable Complications of Total Elbow Replacement: A Report of Two Cases

[x] Jaehon M. Kim MD, [xx] Jesse B. Jupiter MD, [xxx] George S.M. Dyer MD

[x] Harvard Combined Orthopaedics Residency Program, Massachusetts General Hospital, [xx] Hand and Upper Extremity Service, Massachusetts General Hospital, [xxx] Department of Orthopaedic Surgery, Brigham and Women's Hospital

INTRODUCTION

Total elbow replacement (TER) is an effective option for end-stage arthritis and severely comminuted fracture of the elbow. The clinical outcome suggests favorable results in 75% of patients with good pain relief and functional restoration[1]. Despite increasing popularity, the elbow prostheses are fraught with high rate of complications, and revision arthroplasty is challenging even to specialists. With five-year survival in some studies as low as 70%, multiple revisions are commonly performed[2, 3]. Each subsequent reoperation increases the risk of implant failure and infection. An elbow becomes nonsalvageable when a significant bone loss and the threat of recurrent infection prevent further prosthetic reconstructive procedures. Final surgical options are morbid, which include flail elbow and arthrodesis. However, if the bone loss spans the almost entire length of the arm or the elbow articulation is severely deformed, even these solutions become limited. Without resorting to amputation, we provide case examples of antibiotic-impregnated cement spacers which were used to treat infection, restore length and provide some degree of stability to elbow function. Informed consents were obtained from both patients.

CASE REPORTS

Case I. A fifty-four year-old male with posttraumatic arthritis status post unstable fascial interpositional arthroplasty underwent a conversion to a semiconstrained TER eighteen years ago. The index elbow replacement lasted two years, and was complicated by loose humeral component and massive distal humeral osteolysis (Figure 1). Patient required a total of two revision TERs and one resection arthroplasty.

[x] Harvard Combined Orthopaedics Residency Program, Massachusetts General Hospital, 55 Fruit Street, WHT 535, MA 02114

[xx] Hand and Upper Extremity Service, Massachusetts General Hospital, Suite 2100 Yawkey Building, 55 Fruit Street, Boston MA 02114

[xxx] Department of Orthopaedic Surgery, Brigham and Women's Hospital, 75 Francis Street, Boston, MA 02115

Corresponding Author:

George S.M. Dyer MD
Harvard Medical School
Department of Orthopaedic Surgery
Brigham and Women's Hospital
75 Francis Street
Boston, MA 02114
Email: gdyer@partners.org
Phone: 617-732-6607
Fax: 617-730-2815

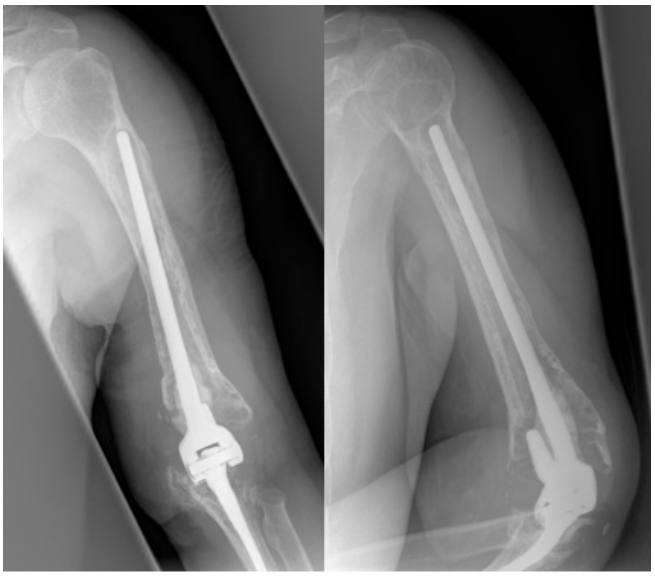

Figure 1: A second revision elbow replacement complicated by massive osteolysis of the humerus. Initially thought to be caused by an infection, no purulent drainage was observed intraoperatively, and cultures were negative.

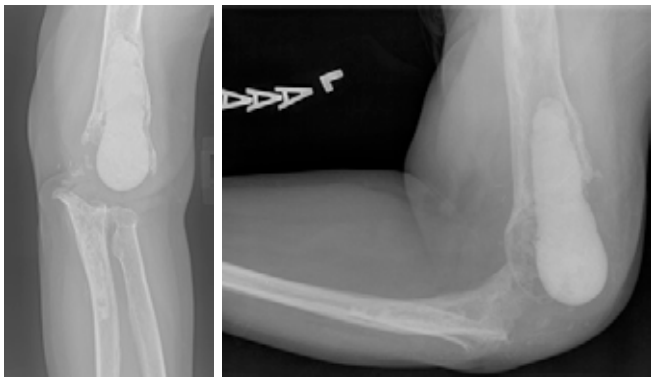

Figure 2: Antibiotic impregnated cement contoured to the shape of distal humerus and proximal radioulnar joint. The tapered edge of distal humerus was thought to be a risk to the friable soft tissues of the elbow.

Due to massive intramedullary bone loss of the humerus, the last revision TER required bone allograft interposition with plate fixation. Acute infection with *Methicillin-Resistant Staphylococcus Aureus* occurred within 3 weeks postoperatively, and despite the effort to retain the implant, patient failed to clear the infection with multiple operative debridements and intravenous antibiotics. Given a distorted shape of the distal humerus and in the setting of a persistent infection, antibiotic impregnated cement spacer was placed (Figure 2). The spacer

Figure 3: Revision arthroplasty using custom endoprosthesis augmented with strut allograft and plate fixation. Major bone deficiency is appreciated between the proximal humerus and distal ulna, measuring approximately 30 cm. Impending periprosthetic fracture is also seen on the humerus around the mid intramedullary stem.

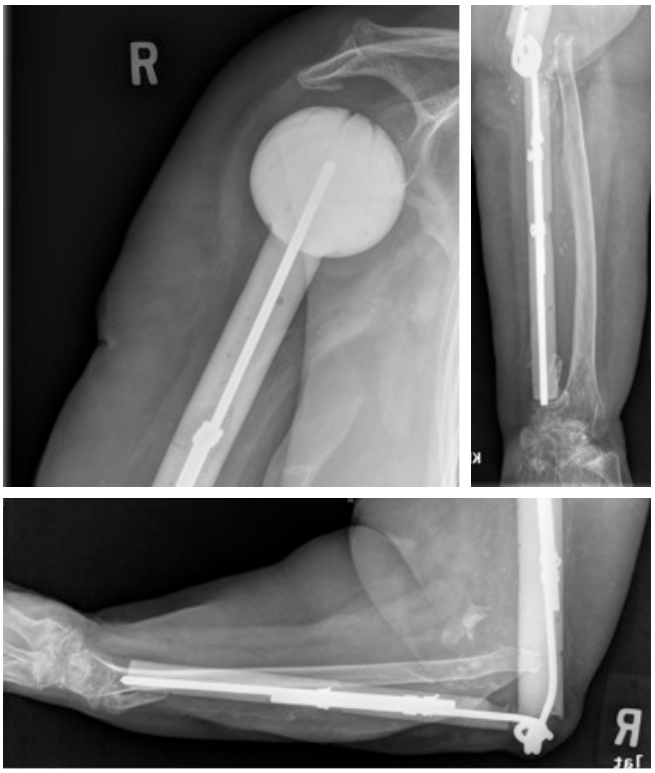

Figure 4: Functional cement spacer custom made using K-wires, a bulb and syringes. Hinge mechanism allowed full extension limited to exactly 170 degrees, and 140 degrees of flexion. The entire functional spacer later rotated partially, limiting the flexion to 130 degrees, and destabilizing the elbow in full extension. No further reconstructions were performed on this patient.

was contoured to smooth the edges of the distal humerus and capture the bone deformation of the proximal radioulnar joint (Figure 2). At the nine year follow-up, the patient maintained good grip strength and pain relief. The lateral instability and deformity of the elbow continued to persist.

Case II. A sixty-two year-old female with a long history of rheumatoid arthritis underwent primary total elbow replacement using a capitellocondylar design twenty-two years ago. Her index implant lasted ten years without major complications. Over the course of next nine years, patient sustained five periprosthetic fractures. The humeral fracture occurred first, requiring a revision arthroplasty to convert the original implant to a semiconstrained system. Subsequent periprosthetic fractures were addressed by using series of strut allograft augmentation and locking plate fixation. Multiple revision arthroplasties led to cumulative loss of native bone, and the elbow was eventually reconstructed using a custom endoprosthesis with strut allograft extension (Figure 3).

Two years after the implant of a custom endoprosthesis, the patient was found to have a grossly infected elbow. Due to absent native bone between the proximal humerus and distal ulna, attempt was made to control the infection with retained implant. A total of eight irrigation and debridement was performed during the course of 8 months with administration of long term intravenous antibiotics. Initial infection revealed erythema and swelling localized around the elbow, but despite exhaustive efforts, the fulminant infection spread longitudinally along the entire arm. Copious purulent drainage was observed around the proximal humeral component, and the sinus tract developed distally around the wrist. The decision was made to resect the implant.

Based on the preoperative measurements, a gap of 30 cm (17 cm on humerus, 13 cm on ulna) would exist between the proximal and distal bone stock (Figure 3). The previous surgical exposure, based posterolaterally about the elbow, was extended to distal ulna and proximally into deltopectoral approach to expose essentially the entire upper extremity. The outcome (or danger) of a flail arm with such length of bone deficit is unknown. In order to provide some stability an internal link was fashioned, custom made out of 3.8 mm K-wire and 18-gauge wire (Figure 4). A bulb syringe and 30-ml syringe were constructed to outline the humeral bone, and a 10-ml syringe barrel was used for the ulnar bone. A tube of cement was casted inside these barrels and allowed to cure. The wire link was inserted into the cement at the correct depth to replicate the location of the elbow joint. Soft tissues were restored with deep muscular attachments sutured in pairs, proximally to distally. At the conclusion of this step, the functional cement spacer was nestled securely within the wound bed of the humerus and ulna (Figure 4).

At fifteen months follow-up the patient was using the arm liberally and was cleared of infection after 15 months. Interestingly, most of the postoperative pain was localized to the wrist but improved over the course of 6 months. The ulnar

component was found to be malrotated 7 months after the surgery, and the hinge mechanism caused limitations in flexion. However despite this limit the patient was satisfied with the functional cement spacer and declined further reconstructive surgery.

DISCUSSION

What defines a nonsalvageable elbow is unclear. Clearly, a massive bone loss and the threat of recurrent infection contribute to the decision of terminating further implant reconstruction. In most instances, it is subjectively determined by the surgeon's preference and expertise. Elbows, in particular, appear to have less resistance against infection, which can lead to large number of surgeries[4]. Antibiotic impregnated cement spacer has been shown to be an effective adjuvant for treating infections of total joint arthroplasties[5]. While some degree of weight bearing is possible with cement spacers[6, 7], it's generally a temporary solution to a staged reconstruction[8].

The upper extremity with less weight bearing needs may tolerate longer placement of cement spacer. We present two cases of functional antibiotic-impregnated cement providing stability and functional assist. Massive osteolysis (case 1) and multiple periprosthetic fractures and pervasive infection (case 2) led to bone deficit that would require complex reconstruction using a custom endoprosthesis. Overwhelming infection in both cases would have undoubtedly led to further implant colonization unless reimplantion was staged. Case 1 presents a distal humeral deformity with tapered edge that would have compromised the soft tissues if left completely flail. The contoured distal humeral cement construct was functional at nine year follow-up. The patient in case 2 had cumulative loss of bone with stepwise reconstruction from strut allografts to endoprosthesis. The highlight of this case was the cement reconstruction of humerus and ulna with K-wire hinge system. The range of motion provided by this construct allowed the patient to use the arm with functional assist at 15 month follow-up.

Articulating (or mobile) cement for prosthetic infections of hip and knee are employed based on surgeon's preference and is an active area of research[8, 9]. Even with weight bearing, the risk of cement fracture is low at less than 5%[6]. Over 90% of the patients went on to have second-stage implantation[6, 8]. The outcome of long term use of cement spacer in elbow as the final salvage procedure is unknown. While bone loss and thin soft tissues are problematic, elbow unlike lower extremity can tolerate certain degree of instability. Very few procedures of this kind are performed in our institutions making it difficult for a larger case series. We suspect that revision TERs will likely increase in the future with broader indications for elbow replacements and increased in surgeon's familiarity. It is important to investigate possible surgical solutions to what we consider a "nonsalvageable" elbow.

References

1. **Schneeberger AG, Meyer DC, Yian EH.** Coonrad-Morrey total elbow replacement for primary and revision surgery: a 2- to 7.5-year follow-up study. J Shoulder Elbow Surg 2007;16:S47-S54.
2. **Aldridge JM, III, Lightdale NR, Mallon WJ, Coonrad RW.** Total elbow arthroplasty with the Coonrad/Coonrad-Morrey prosthesis. A 10-to 31-year survival analysis. J Bone Joint Surg Am 2006;88-B:509-14.
3. **Kraay MJ, Figgie MP, Inglis AE, Wolfe SW, Ranawat CS.** Primary semiconstrained total elbow arthroplasty. Survival analysis of 113 consecutive cases. J Bone Joint Surg Br 1994;76-B:636-40.
4. **Yamaguchi K, Adams RA, Morrey BF.** Infection after total elbow arthroplasty. J Bone Joint Surg Am 1998;80-A:481-91.
5. **Cui Q, Mihalko WM, Shields JS, Ries M, Saleh KJ.** Antibiotic-impregnated cement spacers for the treatment of infection associated with total hip or knee arthroplasty. J Bone Joint Surg Am 2007;89:871-82.
6. **Hsieh PH, Chen LH, Chen CH, Lee MS, Yang WE, Shih CH.** Two-stage revision hip arthroplasty for infection with a custom-made, antibiotic-loaded, cement prosthesis as an interim spacer. J Trauma 2004;56:1247-52.
7. **Klekamp J, Dawson JM, Haas DW, DeBoer D, Christie M**. The use of vancomycin and tobramycin in acrylic bone cement: biomechanical effects and elution kinetics for use in joint arthroplasty. J Arthroplasty 1999;14:339-46.
8. **Durbhakula SM, Czajka J, Fuchs MD, Uhl RL**. Spacer endoprosthesis for the treatment of infected total hip arthroplasty. J Arthroplasty 2004;19:760-74.
9. **Meek RM, Masri BA, Dunlop D, et al.** Patient satisfaction and functional status after treatment of infection at the site of a total knee arthroplasty with use of the PROSTALAC articulating spacer. J Bone Joint Surg Am 2003;85:1888-92.