Complications of Total Elbow Arthroplasty
Subspecialty: Shoulder and Elbow

[x] Jaehon M. Kim MD, [xxx] Chaitanya S. Mudgal MD, MS (Orth.) MCh (Orth.), [xx] Joseph Konopka BA MSc, [xxx] Jesse B. Jupiter MD

[x] Harvard Combined Orthopaedics Residency Program, [xx] Harvard Medical School, 25 Shattuck Street, [xxx] Hand and Upper Extremity Service, Massachusetts General Hospital

ABSTRACT

With a greater understanding of the requirements for a successful total elbow arthroplasty, design modifications and technique improvements have expanded the applications of implant arthroplasty. Unfortunately, complications continue to plague the reconstructive elbow surgeons and often lead to profound and at times nonsalvageable disability. Among the more recognized complications are implant loosening, periprosthetic fracture, infection, nerve palsy and triceps insufficiency. While the number of elbow arthroplasties performed are far less than those in the lower extremity, the proportion of complications are greater and the outcomes of secondary reconstruction less favorable.

INTRODUCTION

Prosthetic replacement of the elbow is an effective treatment for painful arthritis as well as for severe fractures of the distal humerus in the elderly. When successfully implanted, total elbow arthroplasty (TEA) can provide significant pain relief and functional restoration. Initial experience, however, was fraught with high rate of failures and revisions[1-6]. Improved understanding of elbow mechanics and arthroplasty complications led to development of a variety of implant designs. Studies are emerging that suggest semi-constrained prosthesis to have lower risk of instability and implant-related problems than other designs[7, 8]. Furthermore, there are increasing evidence that support the overall efficacy of TEA with wider indications[9, 10]. However, elbow arthroplasty is a relatively infrequent procedure and available literature is limited. In order to optimize outcomes of TEA, many investigators have focused their efforts on understanding complications, and developing revision techniques.

[x] Harvard Combined Orthopaedics Residency Program, 55 Fruit Street, MA 02114
[xx] Harvard Medical School, 25 Shattuck Street, Boston, MA 02115
[xxx] Hand and Upper Extremity Service, Massachusetts General Hospital, Suite 2100 Yawkey Building, 55 Fruit Street, Boston Mass 02114

Corresponding Author:

Jesse B. Jupiter MD
Hansjorg Wyss/AO Professor Orthopaedic Surgery
Harvard Medical School
Chief Hand and Upper Extremity Service
Massachusetts General Hospital
Suite 2100 Yawkey Building
55 Parkman Street, Boston Mass 02114
Email: jjupiter1@partners.org

PRIMARY TOTAL ELBOW ARTHROPLASTY

In early 1970s and 80s, the most common indication for TEA was rheumatoid arthritis (50-75%), followed by post-traumatic arthritis (20-30%)[11, 12]. With advances in antirheumatic drugs, there has been distinct trend towards more traumatic conditions (50-65%) compared to inflammatory arthritis (15-45%)[6, 8, 13, 14]. Other conditions include acute distal humerus fractures, hemophilia, juvenile rheumatoid arthritis, and tumors[9-11]. Multiple studies have demonstrated that TEA's are ideally suited for elderly rheumatoid patients with low functional demand and a severely painful elbow (Table 1)[11]. Overall, rheumatoid patients tend to have better outcome scores, less reoperations and longer implant survival[8, 10-12, 15]. In younger populations, elbow arthroplasty is generally not advocated regardless of the fracture pattern, and an initial attempt is made at internal fixation[10, 11].

Favorable	Unfavorable
Elderly patients (> 65 years)	Younger patients
Low functional demand	Active lifestyle
Significant elbow pain	Limited range of motion only
Loss of daily function	Risk of noncompliance to postoperative protocol
Severely comminuted intra-articular distal humerus fracture	
Advanced inflammatory arthritis	

Table 1: Indications for total elbow arthroplasty.

There are three main designs: unlinked (or unhinged), constrained linked and semi-constrained linked implants. Constrained linked elbow arthroplasty employs a simple hinged mechanism with less than 1° varus-valgus laxity. Mid-to-long term investigations revealed unacceptable rate of implant loosening[7]. Unlinked elbow arthroplasty (also referred to as "unhinged" or "resurfacing") lacks the hinged mechanism, and relies on soft tissue for stability. Using this prosthesis, elbow anatomy is better replicated and allows for ligaments and capsules to dissipate energy transmission. Recent studies, however, revealed that unlinked designs have a similar aseptic loosening rate as constrained linked designs[1, 7] but in addition also has an increased risk of instability[16]. Semi-constrained linked implants utilize a "loose" hinged mechanism allowing for 7° - 10° of varus-valgus laxity and 7° - 10° of axial rotation[13, 17]. Inherent stability of the design

allows for less dependence on surrounding capsuloligamentous structures, and the laxity of the hinge system is thought to decrease the incidence of aseptic loosening[7, 8, 14, 15]. Overall, there is a growing preference for semi-constrained TEA for primary procedures.

Prosthetic arthroplasty of the elbow is comparatively younger than other joint arthroplasties, and is performed less frequently. Therefore, the long-term outcome studies are limited. There has been steady improvement with TEA outcomes since the early 1970s, but it still remains significantly inferior to that of hip and knee arthroplasties. Excellent-to-good or "satisfactory" outcomes can be reliably expected in greater than 75% of the patients with majority scoring 90 or above in a 100 point scale in various outcome instruments[6, 10, 13]. Five-year survival of TEA is approximately 70-90%[18]. From selected literature the results of elbow, knee and hip arthroplasties are shown on table 2[8, 10, 13-15, 18-35].

MECHANISMS OF FAILURE

Elbow kinematics. Stress and energy dissipation at the bone-implant interface can be minimized by accurately reflecting elbow kinematics. The flexion-extension axis is located along the centers of capitellum and the trochlea, and internally rotated 3-8° with respect to the epicondylar plane[36]. Despite optimal positioning, implantation of prostheses can lead to 4-6mm of anterodistal translation in the axis of rotation without detrimental consequence[37]. Some displacement appears unavoidable due to an anterior bow of the humeral component and the shape of medullary canal[37]. Proximal placement of humeral component reduces the flexion strength due to muscle shortening[37], and the distal fixation has higher incidences of complications including nerve palsy and soft tissue tension[38]. The flexion-extension arc is further influenced by rotational positioning and depth of the ulnar implant. External rotation can limit full extension with a mean deficit of 30°, and a deep seated implant can impinge on the humeral component to restrict flexion[6, 37] (Figure 1).

Cadaveric studies revealed that normal intact elbows are semi-constrained in nature with approximately 3° varus-valgus laxity[17, 37]. With TEA implantation, mean varus-valgus deviation was 5° without stress, and 11°-13° with stress[17, 37]. The carrying angle averaged 12° valgus and remained relatively constant throughout the flexion and extension[36].

	TEA			THA			TKA		
	Overall	RA**	<45y†	Overall	RA**	<55y†	Overall	RA**	<55y†
Outcomes (0-100)‡									
Preoperative	38 - 44	38 - 42	37	51	-	-	42	41 - 64	36 - 55
Postoperative	84 - 91	87 - 94	91	91	-	-	82 - 85	85 - 86	84 - 92
% satisfactory	98	89 - 91	93	87.5	96	96	92	-	94
Revision/Reoperation (%)	9.7 - 31.7	8.8 - 12.8	21.8	4.0 - 13	6.8	8.3 - 29.0*	4.5 - 6.5	12.8*	2.7 - 6.1
Aseptic loosening	7.1 - 13.5	1.8 - 2.6	7.3	4.0 - 8.6	1.9	3.3 - 22.5*	1.8 - 2.7	10.3	1.4
Infection	4.9 - 8.1	2.6 - 5.9	3.6	1.3 - 2.0	2.9	2.1 - 4.3	0.7 - 0.9	4.3	1.8
Periprosthetic fracture	5.4 - 23.1	6.4 - 11.8	-	0.4	-	1.1 - 2.1	1.8	0.9 - 2.1	-
PE/Bushing wear	12.5	-	5.5	0.7	-	8	0.7 - 1.0	10.6	0.9 - 1.4
Dislocation/instability	-	-	-	0.4 - 2.0	10.7	1.1	0.7 - 1.8	20.1	1.4 - 2.6
Patella/triceps related	2.7 - 7.7	1.5 - 3.8	-	-	-	-	3.3	1.7	1.4 - 2.6
5-year survival	72 - 84	94.4	-	95+	-	95+	96 - 100	93	95+
10-year survival	≈ 55	92.4	-	94 - 95	93	79 - 95+	91 - 100	80 - 100	95+
> 15-year survival	-	-	-	75+	-	70 - 85+	84 - 94	94 - 100	90

*For TEA, only the semi-constrained linked implants are presented here for comparison. The rate of revisions for TKA and THA are higher than 5 to 10 year follow-up because some studies include 20-year follow-up outcomes. No such comparable TEA literature is available.
**Rheumatoid or inflammatory arthritis patients only.
†for TEA, <45 years old; for TKA, <55 years old; for THA, <55 years old.
‡Outcome measures are conducted using various instruments. For elbows, Mayo Elbow Performance score was used. For knees, Knee Society Knee score or HSS Knee Score were used. For hips, Harris Hip score was included.

Table 2: Mid-to-long term outcomes of primary joint arthroplasties published in 1990s and 2000s.*

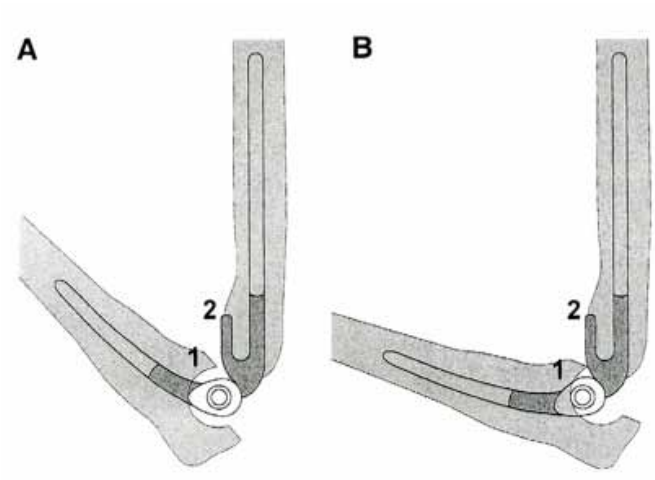

Figure 1. Correct depth of ulnar component with coronoiplasty (1) allows for flexion (A). Deep positioning of the ulnar implant restricts flexion due to impingement with anterior flange of the humeral component (2) (B). (Adapted with permission of Schneeberger AG, Meyer DC, Yian EH. Coonrad-Morrey total elbow replacement for primary and revision surgery: A 2- to 7.5-year follow-up study. J Shoulder Elbow Surg 2007;16:47S-54S.)

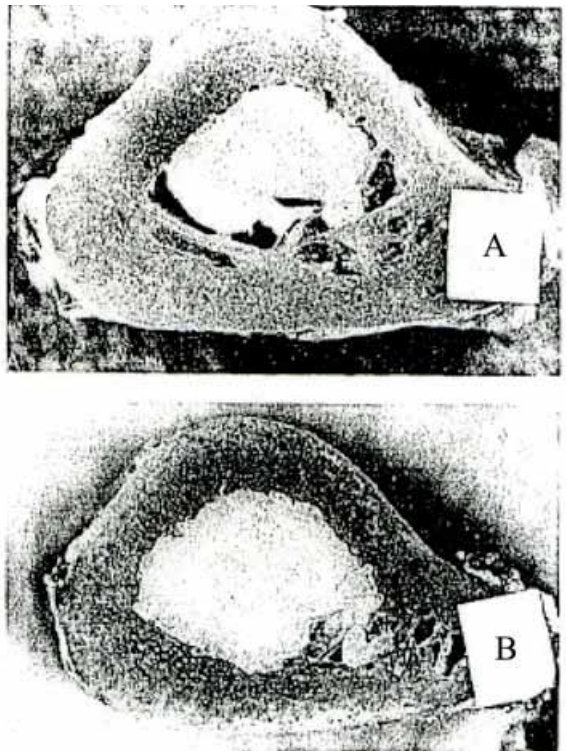

Figure 2. Cross sectional views of the humerus after cementation using a conventional method (manual packing) (A), and the advance technique (B). (Adapted with permission of Faber KJ, Cordy ME, Milne AD, Chess DG, King GJW, Johnson JA. Advanced cement technique improves fixation in elbow arthroplasty. Clin Orthop Relat Res 1997;334:150-156.)

Both native and implanted elbow demonstrated that the mean flexion arc remained relatively centered, but the elbow prosthesis was closer to the structural limit with tendency toward valgus[37]. Internal and external rotation of the humeral component greater than 10° can cause excessive valgus and varus angulation at the hinge, respectively[37]. The destruction of normal joint in post-traumatic and rheumatoid cases can obscure anatomic reference points, and the disruption of musculoligamentous balance can alter normal elbow kinematics. Incremental alterations in implant position and the end result of disease progression can accumulate to distort elbow motion to the limit of implant design, and cause progression of wear with years of use.

Bone stock. Inflammatory erosion and post-traumatic bone loss can affect implant fixation during primary arthroplasty. Unlike the femur or tibia, cortical bone is limited around the elbow and subject to severe osteoporosis in the setting of rheumatoid arthritis and steroid use. Metaphyseal bone and poor vascularity may contribute to increased risk of fracture and bone resorption, and thus, both components are routinely cemented. Adequate fixation is possible, but it appears that there is a less resistance to aseptic loosening.

Surgical solutions compensating for poor bone stock involve augmentative procedure such as impaction bone grafting and strut allograft placement. The purpose is to improve local bone stock and support implant fixation. Majority of the patients demonstrate greater than 50% allograft incorporation to host bone, but implant loosening and periprosthetic fracture continue to persist in approximately one-fifth of patients[39].

Soft tissues. Soft tissue protection around the elbow after surgery may be limited, and lead to difficulty with wound closure. Multiple layers of tissues around the elbow are seldom available unlike other joints. With a posterior incision, lack of thick fibrous fascia contributes to poor resistance to tension and wound breakdown with a consequent higher risk of infection[3, 40]. Even minor wound dehiscence after TEA exposes deep tissues and implants to skin flora. Surgical dissection requires development of thick skin and subcutaneous layers to preserve vascular supply and adequate coverage. Revisions using tension wires or plates can cause significant prominence of implants and discomfort. Scar contracture, bony/implant prominence and tissue edema prevent wound closure, and various soft tissue flaps must be considered in order to provide adequate coverage. Local or distant skin grafts are not generally recommended as a sole coverage of defect, given the already poor vascularity[5]. Local muscle rotational flaps (*i.e.* flexor carpi ulnaris or extensor carpi radialis longus) for small defects and distant muscle pedicle flaps (*i.e.* latissimus dorsi) for larger defect can provide soft tissue coverage. These vascularized flaps also allow for early range of motion and can restore functional deficits simultaneously[5].

COMPLICATIONS

Aseptic implant loosening. The incidence of clinically significant implant loosening is estimated to be 7-15%, and documented radiolucency is even higher[7, 14, 18]. In severe cases, component migration and periprosthetic fractures can ensue. Traditionally, fixed or constrained hinged elbow prostheses are associated with a higher rate of loosening, and semi-constrained hinged system is preferred in most primary elbow cases.

Inadequate cementing technique can lead to irregularity of cement-bone interface and can cause abrasion to the inner cortex[11]. Advanced cementing techniques consist of irrigation

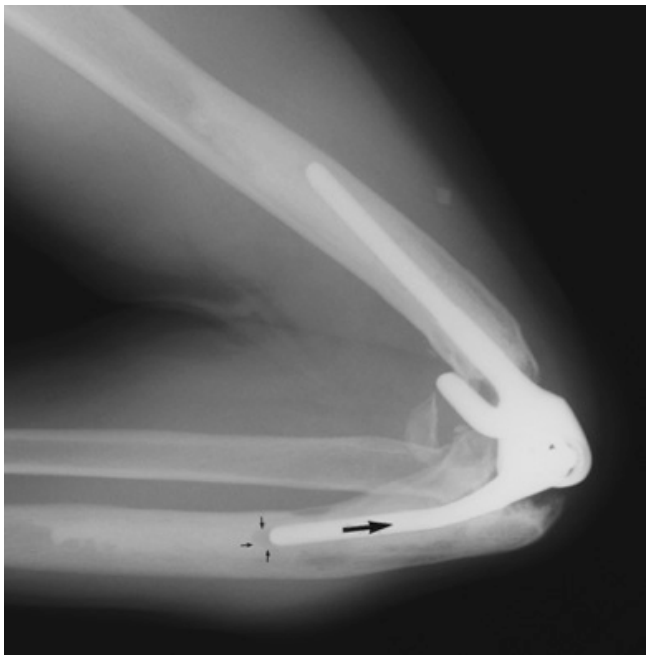

Figure 3. Impingement pistoning of the ulnar stem with elbow flexion. The coronoid process and anterior humeral flange are in contact with migration of ulna (large arrow) and radiolucency (small arrows). (Adapted with permission from Cheung EV, O'Driscoll SW. Total elbow prosthesis loosening caused by ulnar component pistoning. J Bone Joint Surg Am 2007;89:1269-1274.)

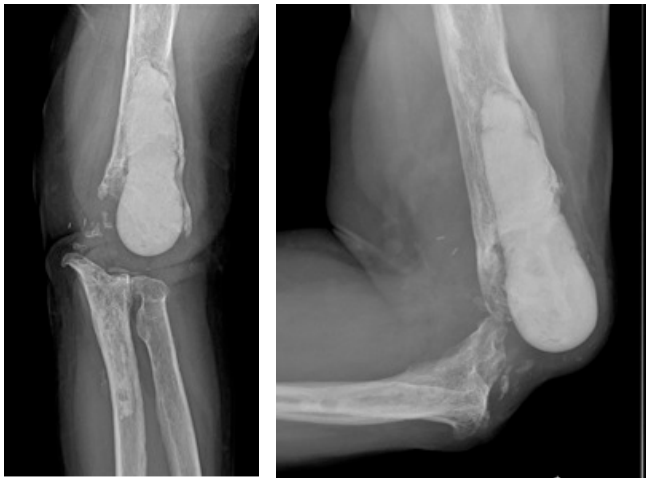

Figure 4. This patient had a long history of complex revisions, and many attempts to stabilize loose implants. Massive osteolysis and distortion of the distal humerus limited reconstructive options. Overwhelming infection eventually required resection arthroplasty and cement ball spacer to replicate the contour of the distal humerus. The patient currently takes suppressive antibiotics, but has good grip strength and only intermittent pain.

of the medullary canal, intramedullary cement plug placement when possible and the use of a cement gun. Irrigation removes biological debris. Intramedullary plug placement allows pressurization, and prevents cement escape in excess beyond the length of the implant stem. The cement gun facilitates uniform filling of the medullary canal. Reduction of voids and laminations, and increased microinterlock fixation was shown to be an important contribution to success in other joint arthroplasties, and has been shown to provide superior mechanical advantage[20, 41]. Qualitative differences between the advanced and conventional cementing (manual insertion) techniques are shown in figure 2.

Impingement pistoning of the ulnar stem with elbow flexion has been also identified to cause loosening[42]. The ulnar stem becomes distracted posteriorly when the elbow is flexed against an impinging structure (Figure 3). An anterior humeral flange and coronoid process can set the limit of flexion in the Coonrad-Morrey prosthesis. A trial of motion must be carefully assessed with particular attention to coronoid process, protruding cement and heterotopic ossification[42].

Several solutions are available for aseptic loosening. Observation is a reasonable course of action when patients are asymptomatic. With instability or pain, revision arthroplasty should be considered. Surgeons should be aware that the most common cause of failure when revising a loosened implant is another implant loosening[1].

Infection. The rate of deep infection after TEA is approximately 3-17%[3, 6, 40]. *Staphylococcus aureus* and *Staphylococcus epidermidis* are common causative organisms[3, 40, 43]. Impregnated cement is commonly used during the index procedure, and may contribute to lower rate of infection[14, 15]. This practice, however, is not routinely employed in hip and knee, and the actual benefits are unclear. In general, treatment requires irrigation and debridement, intravenous antibiotics, and possible resection arthroplasty. We found that infection leads to the greatest number of return to the operating room for multiple debridements and prosthetic revisions than any other complications. Retention of the original implant may be attempted but the risk of failure is high at 50-75% and many will eventually require implant removal[3, 40]. Symptom of infection less than 3 - 4 weeks and no radiologic evidence of lucency are associated with higher rate of success[3, 44].

After the eradication of infection, the option for reconstruction is based on the assessment of clinical and radiographical findings. Unlike other major joints, reimplantation should be approached with caution and is not always recommended[3, 40]. A thin friable soft tissue envelope, damaged vascularity, and loss of bone stock from prior cement removal can limit available options[45]. A small case series of one-stage debridement and exchange arthroplasty was reported with success in five out of six patients[43], but this does not appear to be the typical outcome. The most effective treatment for treating infection appears to be resection arthroplasty. Without a functional elbow joint, lateral instability can be profound, but pain and motion may be surprisingly acceptable to select patients[3, 45]. Intractable and overwhelming infection may require antibiotic cement spacer placement in addition to removal of dead bone (Figure 4).

Periprosthetic fracture. Periprosthetic fracture has been reported by O'Driscoll *et al* to occur in 5% of primary TEA's[4]. Trauma is only one of the many causes. Ostetoporosis, aseptic loosening, stress shielding, poor technique and noncompliance to activity restrictions significantly contribute to this problem. Most patients have history of multiple operations such as ORIF and failed TEA prior sustaining the fracture. The Mayo classification of elbow periprosthetic fractures incorporates the site of fracture, fixation of the implant, and the quality of bone stock[4] (Table 3). Not all fractures require

Fracture	Description	Type
Humerus		
H-I	Fracture of the column or condyles	
H-II	Fracture around the stem	
H-II 1	Implant well fixed	
H-II 2	Implant loose with acceptable bone stock	
H-II 3	Implant loose with severe bone loss	
H-III	Fracture proximal to stem	
Ulna		
U-I	Fracture of the olecranon	
U-II	Fracture around the stem	
U-II 1	Implant well fixed	
U-II 2	Implant loose with acceptable bone stock	
U-II 3	Implant loose with severe bone loss	
U-III	Fracture proximal to stem	

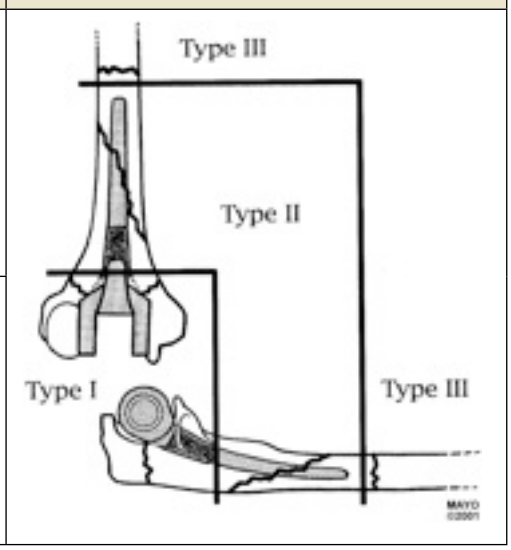

Table 3. Mayo Classification of Periprosthetic Fractures of the Elbow[4]

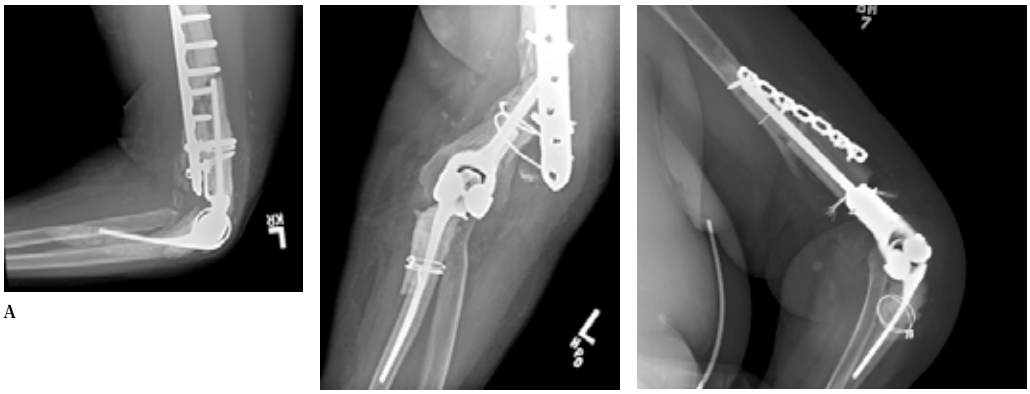

A B C

Figure 5. This was a referral patient who underwent TEA after post-traumatic arthritis. Multiple complications occurred including infection managed with resection arthroplasty, and reimplantation, which subsequently led to a periprosthetic fracture. The ulnar component eroded out of intramedullary canal, and impending fracture of the humerus was evident despite plate and screw fixation (A). Complete fracture of the humerus was observed after the first procedure of planned staged revision (B). Revision arthroplasty required custom prosthesis with multiple strut allografts and plate fixation (C). Latest follow-up showed aseptic loosening of the humerus.

operative fixation, and the treatment can also vary depending on the timing of fracture (*i.e.* intraoperative vs. postoperative).

Humeral condyles and the olecranon are common sites of fracture. Nondisplaced fractures can be treated symptomatically with a period of immobilization. Many patients will go onto have a fibrous nonunion, and the degree of functional loss depends on the attached musculatures of condyles[4]. Common extensors and flexors arising from the condyles are important stabilizers of the elbow, and the loss of triceps function can significantly affect the arc of motion. Furthermore, the outcome of resection arthroplasty, if ever needed, relies heavily on these muscles for both function and stability[4]. If the displacement is significant, ORIF may be preferred. Due to the presence of elbow prosthesis, heavy nonabsorbable sutures or tension band wiring may be the only available options.

Humeral and ulnar shaft fractures within the length of the stems typically require revision arthroplasty. The actual cause of periprosthetic fracture must be carefully explored. Poor implant position, osteolysis and aseptic loosening can contribute to the problem, and should be appropriately addressed during the revision surgery. Use of a long-stem prosthesis, strut allografting, and impaction bone grafting may be required for reconstruction (Figure 5). The fractures not involving the length of the prosthesis can be treated similar to routine fracture care. Typically, immobilization for humeral shaft fracture or plate fixation for ulnar fractures is recommended.

Triceps insufficiency. Various posterior exposures are utilized for elbow arthroplasty. As the techniques evolved, many approaches have been attempted to reduce the incidences of soft tissue complications. The triceps, in particular, serves two important functions. First, adequate extension of the elbow is solely dependent on the triceps. Functionally, patients have difficulty with reaching over the head and pushing open doors[46]. Secondly, muscle coverage around the implant provides a thick soft tissue envelope which can augment the already thin coverage around the elbow. This may reduce wound complications and exposure to deep infections[47]. The overall prevalence of triceps insufficiency ranges from 2 to 12.5%[8, 11, 46]. In rheumatoid patients, the erosion of the olecranon and tenuous triceps tendon are at risk of avulsion fractures or tendon ruptures. Nonunion of olecranon fractures in setting of posttraumatic arthritis and multiple revisions can also lead to compromised function of the triceps.

Prevention against this complication has been addressed

by using different surgical approaches and meticulous repair of the triceps. A straight dorsal incision is most often used, but the exposures of elbow joint beneath the triceps differ significantly. Direct elevation of the triceps or an olecranon osteotomy is becoming less frequent for primary TEAs, but remains an option for revisions[45, 48]. The triceps splitting and triceps reflecting approaches are aimed at preserving the continuity of extensor mechanism. Complete loss of triceps function with the newer approaches is uncommon[47], but weakness can still persist. Post-operatively, the mean strength of the triceps is 20% more with a triceps reflecting approach when compared to other exposures[49]. The triceps preserving approach is a bilateral tricipital approach using a single posterior incision. No detachment of triceps from olecranon is required and adequate exposure to both radial and ulnar sides of the elbow can be obtained[47].

The treatment of triceps disruption is mainly surgical. Various options for reconstruction exist, but augmentative procedures using Achilles tendon allograft (80% success) or anconeus rotational flap (100% success) appears to be superior to direct repair for restoring triceps function. The quality of the olecranon and triceps must be carefully addressed during the repair. Achilles tendon with a calcaneus fragment or patellar allograft can be used for triceps insufficiency with a deficient olecranon, and bony stability can be achieved by screw fixation[46] (Figure 6).

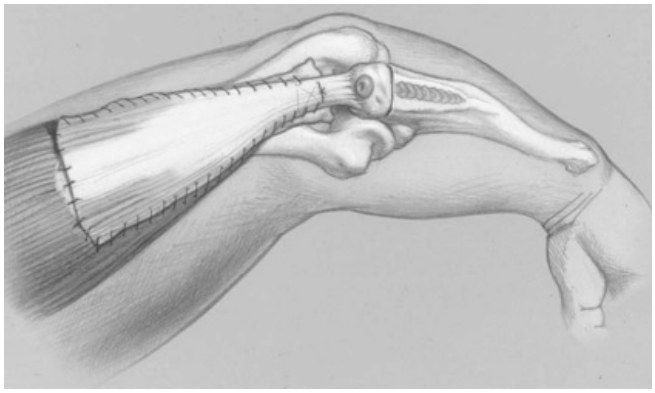

Figure 6. Augmentation of deficient triceps and olecranon using Achilles tendon and calcaneus allograft. (Adapted with permission of Mayo Foundation.)

Implant failure. Implant wear and osteolysis may contribute to early failures in TEA[2]. Bushing or polyethylene wear has been identified in semi-constrained linked elbow implants[1]. Clinically significant bushing wear that requires isolated exchange is estimated to be approximately 1.3%[50]. Surgical results are generally favorable when no other problems are found. McKellop HA *et al* performed a postmortem implant analysis of TEAs, which revealed bushing wear in all patients with elbow prosthesis[51], and titanium alloy and polyethylene wear particles were abundant in periarticular soft tissues[2]. Particles generated from the two expected interface (*i.e.* bushing and axl) and third-body interposition were present in nearly all cases, and about half of the implants exhibited particle generation from nonintended articulations (*i.e.* humeral and ulnar component) (figure 7). Excessive bushing wear may cause pain and instability, and subsequent inflammatory



Figure 7. Proximal wear of polyethylene bushing (A) and metal-on-metal wear of the ulnar component (B). Unintended articulation of humeral and ulnar component (black arrow), and contact between condylar segment and bone/cement of ulna (white arrow) (C). (Adapted with permission of Goldberg SH, Urban RM, Jacobs JJ, King GJW, O'Driscoll SW, Cohen MS. Modes of wear after semicon-strained total elbow arthroplasty. J Bone Joint Surg Am 2008;90:609-19.)



Figure 8. Implant fracture at the junction of ulnar bone fixation and unsupported periarticular segment. (Adapted with permission of Shafer BL, Fehringer EV, Boorman RS, Churchill RS, Matsen FA 3rd. Ulnar component fracture after revision total elbow arthroplasty with proximal ulnar bone loss: a report of 2 cases. J Shoulder Elbow Surg 2003;12:297-301.)

response with osteolysis predisposes the patient to implant loosening.

Implant fractures are uncommon. A case series by Athwal GS *et al* estimates 1.2% prevalence of humeral component fracture with average time of 8.2 years between implantation and fracture, and 0.65% prevalence of ulnar component fracture with average time of 4.6 years before the fracture[48]. Higher incidences were noted among patients with trauma-related arthroplasties (74%) as opposed to rheumatoid arthritis (22%). In a study involving femoral component of the hip prosthesis, proximal bone loss, osteotomy nonunion and periprosthetic fracture are some of the factors that can significantly elevate stress within the implant by as much as 82-100%[52]. Similarly in the elbow, over ninety percent of the implants show evidence of bone loss, and the excessive tensile stress at the junction of well-fixed stem and unsupported periarticular region was thought to be the cause of the fatigue fracture[48, 53] (Figure 8). The surgical management consists of removal of fractured implant, and revision arthroplasty with insertion of a larger diameter implant if possible.

Instability. Hinged elbow arthroplasties can become unstable secondary to aseptic loosening, implant fracture and loss of the hinge mechanism. Profound instability leading to subluxation and dislocations, however, are generally associated with unhinged designs[1, 16]. Without captive articulation, the stability of the replacement relies heavily on soft tissue balance and accurate restoration of the anatomic axis. Instability is the cause of as many as 55% of revisions on unlinked prosthesis, and retaining the index implant often results in persistent instability (6 out of 9 failures)[16]. Reconstruction of collateral ligament and revision of components can be attempted, but most patients will eventually require semi-constrained hinged arthroplasty for stability[16].

Neuropathy. Two nerves of functional importance are exposed during the surgical dissection of the elbow. The ulnar nerve traverses anterior to medial head of the triceps and medial to the olecranon process. In order to protect the nerve, it must be released from several anatomic locations, which include the medial intermuscular septum, cubital tunnel and the fascia bridging the two heads of the flexor carpi ulnaris. Ulnar paresthesias are common (as high as 40%) postoperatively although most patients have resolution of symptoms over time[12, 14, 15]. Direct lacerations are rare since the nerve is protected under direct vision, but traction and thermal injuries are possible and often unrecognized during cementing and instrumentation.

The radial nerve, which crosses the elbow joint anterolaterally, is further away from the surgical field, and has a lower incidence of inadvertent injury. It is not routinely exposed or released. During explantations or revisions, however, the radial nerve is at risk. Proximal extensile exposure of the humerus crosses the radial nerve at approximately 15cm from the medial condyle[54]. It courses medial to lateral underneath the lateral head of the triceps. Cortical penetration by a reamer[16], cement extrusion at the site of periprosthetic fractures[12] and humerus resection during endoprosthesis implantation[38, 55] are some of the potential and documented causes of radial nerve injury.

The ulnar nerve is frequently affected, and some surgeons perform routine transposition during the primary elbow arthroplasties[8, 11]. The timing for re-exploration is uncertain, but generally an adequate waiting period is recommend (>6 weeks)[12]. Diagnostic tests usually consist of plain radiographs and nerve conduction studies. Cement and extensive scarring may impair the quality of the nerve, making it unrepairable with poor healing potential. Tendon transfers may provide partial return of function with radial nerve palsy, but not recommended for the ulnar nerve[16, 38].

SURGICAL PRINCIPLES

Resection arthroplasty. The management of most elbow prosthetic failure starts with resection arthroplasty. The margin of error for successful surgical outcome is small, and subsequent revision procedures are critically dependent on what is left of the native bone after implant removal. Preservation of bone stock and meticulous care of soft tissue can positively alter the strategies for reconstruction.

Resistant infections that require removal of prostheses are treated with extensive debridement of all necrotic materials including bone, cement and soft tissues. Reducing bacterial load is of primary importance. Multiple irrigation and debridements are needed in the majority of patients, and some may require over 10 procedures to eradicate the infection[3, 40]. The loss of soft tissue vascularity due to repeated dissections and extensive scarring must be considered along with plans for possible flap closure. Due to a high rate of recurrence (as high as 30%), any plan for reimplantation should be approached with extreme caution[3, 40]. Retaining humeral condyles, which are at risk of fracture, provides stability to a flail elbow and also serves as an anatomic containment of the olecranon[40].

In a setting of aseptic loosening, minimizing bone loss for future reimplantation is critical. When implants are grossly unstable, the stem with cement mantle can be easily extracted. In cases of total revision where firmly fixed implant needs removal, options to aid in cement and resection include the vise-grip with slap hammer, powered drills/burrs and small osteotomes . If refitting of the implant is not possible due to cement interference, then either an osteotomy or a cortical window may be required for complete cement removal[48].

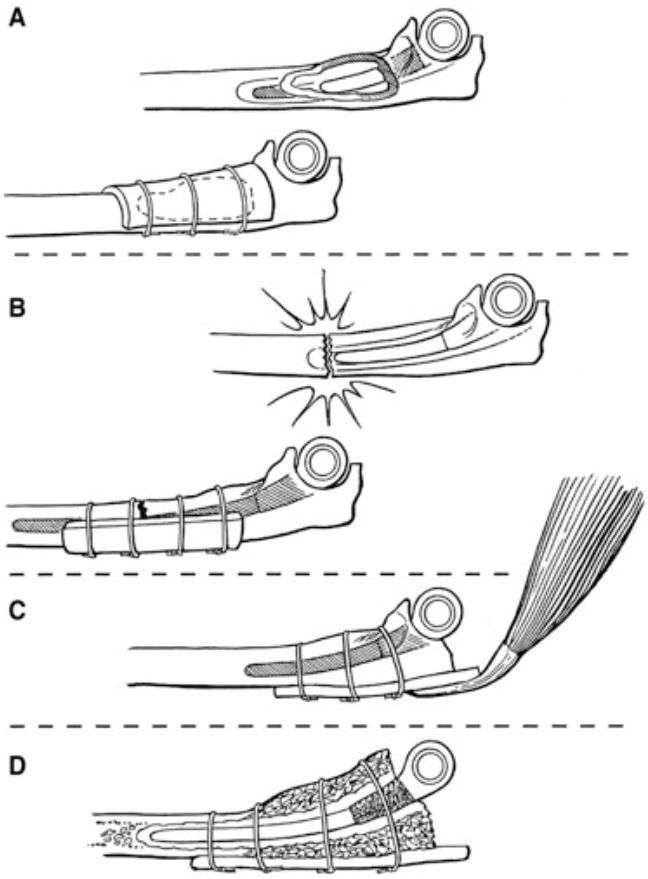

Figure 9. Various ulnar deficiencies, such as cortical defect (A), periprosthetic fracture (B), olecranon defect (C) and thin cortex (D), are augmented with a combination of strut allograft, impaction bone grafting and cerclage wire. (Adapted with permission of Kamineni S, and Morrey BF. Proximal ulnar reconstruction with strut allograft in revision total elbow arthroplasty. J Bone Joint Surg Am 2004;86-A:1223-1229.)

Revision arthroplasty. The elbow can be reconstructed after TEA failure to achieve functional range of motion and pain relief. The rate of complications can be as high as 50%, and further revision is likely needed in 20% of patients[48]. Several basic principles apply. Careful preoperative planning is mandated with special attention to bone stock and implant choice. Computed tomography scans are helpful for closer examination of cortex and the cement mantle. The distal anterior cortex of the humerus, and prior osteolysis around the ulna are thought to be the areas of high stress, with a high potential for failure[2, 15]. In majority of the cases, semi-constrained linked designs are the preferred choice with an option for longer stems[1, 16]. Advanced cementing techniques should be applied in all revisions, and augmentative bone allografts should be aggressively used if bone loss is present. Intraoperative periprosthetic fractures or cortical perforations are particularly common in elbow revisions[16, 39, 48].

Revision arthroplasty must address the initial mechanism of failure. Aseptic loosening needs additional support for the poor bone stock in the intramedullary canal, and the new implant should restore mechanical alignment of the elbow joint accurately. Careful observation of the failed instrumentation and correlation with radiographs can provide clues to mode of wear[2]. Reimplantation after infection can be successful in a small subset of patients with a highly sensitive organism, good bone and soft tissue quality[40, 43]. After multiple operations, devascularized tissues are potential sources for seeding infections, and should be excised. Antibiotic impregnated cement (1g tobramycin in 40g cement) is almost always used, and anecdotally thought to decrease the rate of infection[15].

Periprosthetic fractures can occur intra- and postoperatively. In most instances, both the humerus and ulna can be augmented in similar fashion with strut allograft fixed with 16 or 18-gauge cerclage wire (Figure 9), as described by Morrey BF *et al*[4, 39]. Attempts should be made to extend the stem and structural graft by at least 2 cortical diameters beyond the osseous lesion[39]. When adequacy of fixation is in doubt, the fracture can be further stabilized using plate and screw fixation with unicortical screw purchase (Figure 5). Cement extrusion through the fracture site must be carefully monitored, as this may cause unrecognized nerve palsies[12] and contribute to poor fixation.

Meticulous soft tissue management by avoiding forceful retractions and minimizing soft tissue trauma is important to eliminate dead space for hematoma collection, and promote wound healing. Closure of wounds under tension is discouraged, and there should be a low threshold for considering local muscle flaps to augment soft tissue coverage.

Custom-fit endoprosthetic arthroplasty. Large segmental loss of distal humerus or proximal ulna after multiple failed revisions is often nonsalvageable. Alternative options are limited to flail elbow, amputation and arthrodesis. Most literature regarding the outcome and techniques in such situations are related to tumor patients[55, 56]. Osteoarticular destruction of the elbow with a large defect may require custom-made endoprosthetic arthroplasty. The entire humerus can be replaced, if needed, along with the elbow joint and proximal ulna. Often the outcome is poor and the rate of complication is high[56]. In few successful cases, the flexion arc averaged 85° with some functional use. Endoprosthetic arthroplasty is typically reserved for patients with multiple surgical failures and severe bone loss, and considered as the absolute last resort to retaining a "serviceable elbow"[55]. The most common complications are nerve palsies, followed by aseptic loosening and infections[55, 56]. Bone resection may be necessary for secure fixation of the implant, but otherwise, similar principles apply to endoprosthetic arthroplasty as they do for revision arthroplasties.

SUMMARY

Total elbow arthroplasty is a viable option for advanced arthritis of the elbow. Among various implant designs, a semi-constrained linked prosthesis is becoming a popular choice among surgeons. Effective pain relief and restoration of function has broadened the surgical indication to include comminuted fractures of the distal humerus, joint ankylosis, and severe elbow instability. Satisfying outcomes can be expected in greater than 75% of patients, but the rate of complications and revisions remains high. Aseptic implant loosening

and infection are common mechanisms of failure. Resection arthroplasty is an important step in surgical management, and requires careful preservation of bones and soft tissues. Revision arthroplasty should be augmented with impaction bone graft or strut allograft to secure adequate implant fixation. Other operative complications include periprosthetic fracture, implant failure, and triceps insufficiency. When successful, elbow revisions can have a favorable outcome. However, some will go onto have multiple operations, and few patients will be left with a flail elbow.

References

1. **Levy JC, Loeb M, Chuinard C, Adams RA, Morrey BF:** Effectiveness of revision following linked versus unlinked total elbow arthroplasty. *J Shoulder Elbow Surg* 2009:18:457-462.
2. **Goldberg SH, Urban RM, Jacobs JJ, King GJ, O'Driscoll SW, Cohen MS:** Modes of wear after semiconstrained total elbow arthroplasty. *J Bone Joint Surg Am* 2008:90:609-619.
3. **Yamaguchi K, Adams RA, Morrey BF:** Infection after total elbow arthroplasty. *J Bone Joint Surg Am* 1998:80-A:481-491.
4. **O'Driscoll SW, Morrey BF:** Periprosthetic fractures about the elbow. *Orthop Clin North Am* 1999:30:319-325.
5. **Stevanovic M, Sharpe F, M IJ:** Treatment of soft tissue problems about the elbow. *Clin Orthop Relat Res* 2000:370:127-137.
6. **Schneeberger AG, Meyer DC, Yian EH:** Coonrad-Morrey total elbow replacement for primary and revision surgery: a 2- to 7.5-year follow-up study. *J Shoulder Elbow Surg* 2007:16:S47-S54.
7. **Little CP, Graham AJ, Carr AJ:** A systematic review of the literature in the Engligh language until the end of 2003. *J Bone Joint Surg Br* 2005:87-A:437-444.
8. **Hildebrand KA, Patterson SD, Regan WD, MacDermid JC, King GJW:** Functional outcome of semiconstrained total elbow arthroplasty. *J Bone Joint Surg Am* 2000:82-A:1379-1386.
9. **McKee MD, Veillette CJH, Hall JA, et al.**: A multicenter, prospective, randomized, controlled trial of open reduction internal fixation versus total elbow arthroplasty for displaced intra-articular distal humeral fractures in elderly patients. *J Shoulder Elbow Surg* 2009:18:3-12.
10. **Celli A, Morrey B:** Total elbow arthroplasty in patients forty years of age or less. *J Bone Joint Surg Am* 2009:91:1414-1418.
11. **Inglis AE, Pellici PM:** Total elbow replacement. *J Bone Joint Surg Am* 1980:62A:1252-1258.
12. **Kasten MD, Skinner HB:** Total elbow arthroplasty. An 18-year experience. *Clin Orthop Relat Res* 1993:290:177-188.
13. **Shi LL, Zurakowski D, Jones DG, Koris MJ, Thornhill TS:** Semiconstrained primary and revision total elbow arthroplasty with use of the Coonrad-Morrey prosthesis. *J Bone Joint Surg Am* 2007:89:1467-1475.
14. **Aldridge JM, III, Lightdale NR, Mallon WJ, Coonrad RW:** Total elbow arthroplasty with the Coonrad/Coonrad-Morrey prosthesis. A 10-to 31-year survival analysis. *J Bone Joint Surg Br* 2006:88-B:509-514.
15. **Morrey BF, Adams RA:** Semiconstrained arthroplasty for the treatment of rheumatoid arthritis of the elbow. *J Bone Joint Surg Am* 1992:74-A:479-490.
16. **Ring D, Kocher M, Koris M, Thornhill TS:** Revision of unstable capitellocondylar (unlinked) total elbow replacement. *J Bone Joint Surg Am* 2005:87:1075-1079.
17. **O'Driscoll SW, An KN, Korinek S, Morrey BF:** Kinematics of semi-constrained total elbow arthroplasty. *J Bone Joint Surg Am* 1992:74:297-299.
18. **Kraay MJ, Figgie MP, Inglis AE, Wolfe SW, Ranawat CS:** Primary semiconstrained total elbow arthroplasty. Survival analysis of 113 consecutive cases. *J Bone Joint Surg Br* 1994:76-B:636-640.
19. **Callaghan JJ, Liu SS, Firestone DE, et al.:** Total hip arthroplasty with cement and use of a collared Matte-Finish femoral component. Nineteen to twenty-year follow-up. *J Bone Joint Surg Am* 2008:90:299-306.
20. **Firestone DE, Callaghan JJ, Liu SS, et al.:** Total hip arthroplasty with a cemented, polished, collared femoral stem and a cementless acetabular component. A follow-up study at a minimum of ten years. *J Bone Joint Surg Am* 2007:89-A:126-132.
21. **Sanchez-Sotelo J, Berry DJ, Harmsen S:** Long-term res ults of use of a collared matte-finished femoral component fixed with second-generation cementing techniques. *J Bone Joint Surg Am* 2002:84-A:1636-1641.
22. **Creighton MG, Callaghan JJ, Olejniczak JP, Johnston RC:** Total hip arthroplasty with cement in patients who have rheumatoid arthritis. A minimum of ten-year follow-up study. *J Bone Joint Surg Am* 1998:80-A:1439-1446.
23. **Callaghan JJ, Forest EE, Olejniczak JP, Goetz DD, Johnston RC:** Charnley total hip arthroplasty in patients less than fifty years old. A twenty to twenty-five year follow-up note. *J Bone Joint Surg Am* 1998:80-A:704-714.
24. **Neumann L, Freund KG, Sorensen KH:** Total hip arthroplasty with the Charnley prosthesis in patients fifty-five years old or less. Fifteen to twenty-one year results. *J Bone Joint Surg Am* 1996:78-A:73-79.
25. **Ballard WT, Callaghan JJ, Sullivan PM, Johnston RC:** The results of improved cementing techniques for total hip arthroplasty in patients less than fifty years old. A ten-year follow-up study. *J Bone Joint Surg Am* 1994:76-A:959-964.
26. **Attar FG, Khaw FM, Kirk LM, Gregg PJ:** Survivorship analysis at 15 years of cemented press-fit condylar total knee arthroplasty. *J Arthroplasty* 2008:23:344-349.
27. **Roberts VI, Esler CNA, Harper WM:** A 15-year follow-up study of 4606 primary total knee replacements. *J Bone Joint Surg Br* 2007:89-B:1452-1456.
28. **Rand JA, Trousdale RT, Ilstrup DM, Harmsen WS:** Factors affecting the durability of primary total knee prostheses. *J Bone Joint Surg Am* 2003:85-A:259-265.
29. **Crowder AR, Duffy GP, Trousdale RT:** Long-term results of total knee arthroplasty in young patients with rheumatoid arthritis. *J Arthroplasty* 2005:20:12-16.
30. **Ewald FC, Wright RJ, Poss R, Thomas WH, Mason MD, Sledge CB:** Kinematic total knee arthroplasty. A 10- to 14-year prospective follow-up review. *J Arthroplasty* 1999:14:473-480.
31. **Duffy GP, Trousdale RT, Stuart MJ:** Total knee arthroplasty in patients 55 years old or younger. 10- to 17- year results. *Clin Orthop Relat Res* 1998:356:22-27.
32. **Diduch DR, Insall JN, Scott WN, Scuderi GR, Rodriguez D:** Total knee replacement in young, active patients. Long-term follow-up and functional outcome. *J Bone Joint Surg Am* 1997:79-A:575-582.
33. **Ranawat CS, Flynn WF, Saddler S, Hansraj KK, Maynard MJ:** Long-term results of the total condylar knee arthroplasty. A 15-year survivorship study. *Clin Orthop Relat Res* 1993:286:94-102.
34. **Laskin R:** Total condylar knee replacement in patients who have rheumatoid arthritis. A ten-year follow-up study. *J Bone Joint Surg Am* 1990:72:529-535.
35. **Gill DRJ, Morrey BF:** The Coonrad-Morrey total elbow arthroplasty in patients who have rheumatoid arthritis. A ten to fifteen-year follow-up study. *J Bone Joint Surg Am* 1998:80:1327-1335.

36. **London J:** Kinematics of the elbow. *J Bone Joint Surg Am* 1981:63:529-535.
37. **Schuind F, O'Driscoll S, Korinek S, An KN, Morrey BF:** Loose-hinge total elbow arthroplasty. An experimental study of the effects of implant alignment on three-dimensional elbow kinematics. *J Arthroplasty* 1995:10:670-678.
38. **Figgie HE, Inglis AE, Mow C:** Total elbow arthroplasty in the face of significant bone stock or soft tissue losses. Prelimary results of custom-fit arthroplasty. *J Arthroplasty* 1986:1:71-81.
39. **Kamineni S, Morrey BF:** Proximal ulnar reconstruction with strut allograft in revision total elbow arthroplasty. *J Bone Joint Surg Am* 2004:86-A:1223-1229.
40. **Wolfe SW, Figgie MP, Inglis AE, Bohn WW, Ranawat CS:** Management of infection about total elbow prostheses. *J Bone Joint Surg Am* 1990:72-A:198-212.
41. **Faber KJ, Cordy ME, Milne AD, Chess DG, King GJW, Johnson JA:** Advanced cement technique improves fixation in elbow arthroplasty. *Clin Orthop Relat Res* 1997:334:150-156.
42. **Cheung EV, O'Driscoll SW:** Total elbow prosthesis loosening caused by ulnar component pistoning. *J Bone Joint Surg Am* 2007:89:1269-1274.
43. **Gille J, Ince A, González O, Katzer A, Loehr JF:** Single-stage revision of peri-prosthetic infection following total elbow replacement. *J Bone Joint Surg Br* 2006:88:1341-1346.
44. **Del Pozo JL, Patel R:** Infection associated with prosthetic joints. *N Engl J Med* 2009:361:787-794.
45. **Inglis AE:** Revision surgery following a failed total elbow arthroplasty. *Clin Orthop Relat Res* 1982:170:213-218.
46. **Celli A, Arash A, Adams RA, Morrey BF:** Triceps insufficiency following total elbow arthroplasty. *J Bone Joint Surg Am* 2005:87-A:1957-1964.
47. **Pierce TD, Herndon JH:** The triceps preserving approach to total elbow arthroplasty. *Clin Orthop Relat Res* 1998:354:144-152.
48. **Athwal GS, Morrey BF:** Revision total elbow arthroplasty for prosthetic fractures. *J Bone Joint Surg Am* 2006:88-A:2017-2026.
49. **Morrey BF, Askew LJ, An KN:** Strength function after elbow arthroplasty. *Clin Orthop Relat Res* 1988:234:43-50.
50. **Lee BP, Adams RA, Morrey BF:** Polyethylene wear after total elbow arthroplasty. *J Bone Joint Surg Am* 2005:87:1080-1087.
51. **McKellop HA:** Wear assessment, in Callahan JJ, Rosenberg AG, Rubash HE (eds): *The Adult Hip*. Philadelphia: Lippincott-Raven, 1998, pp 231-246.
52. **Crowninshield RD, Maloney WJ, Wentz DH, Levine DL:** The role of proximal femoral support in stress development within hip prostheses. *Clin Orthop Relat Res* 2004:420:176-180.
53. **Shafer BL, Fehringer EV, Boorman RS, Churchill RS, Matsen FA, 3rd**: Ulnar component fracture after revision total elbow arthroplasty with proximal ulnar bone loss: a report of 2 cases. *J Shoulder Elbow Surg* 2003:12:297-301.
54. **Gerwin M, Hotchkiss RN, Weiland AJ:** Alternative operative exposures of the posterior aspect of the humeral diaphysis. With reference to radial nerve. *J Bone Joint Surg Am* 1996:78:1690-1695.
55. **Ross AC, Sneath RS, Scales JT**: Endoprosthetic replacement of the humerus and elbow joint. *J Bone Joint Surg Br* 1987:69-B:652-655.
56. **Weber KL, Lin PP, Yasko AW:** Complex segmental elbow reconstruction after tumor resection. *Clin Orthop Relat Res* 2003:415:31-44.