

A PROGRAM OF RESEARCH IN DISTRACTION OSTEOGENESIS

JULIE GLOWACKI, PH.D.

DEPARTMENT OF ORTHOPAEDIC SURGERY, BRIGHAM AND WOMEN'S HOSPITAL, BOSTON MA

INTRODUCTION

Distraction osteogenesis (DO) is a technique for skeletal lengthening that exploits the body's innate capacity for bone formation in response to tension forces on fracture callus. DO can also be described as a controlled series of microfractures through repair tissue that results in the elongation of the fracture gap and its maturation into bone (Figure 1a). The primary operation is of lesser magnitude than standard acute bone lengthening and a graft donor site operation is avoided.

The technique was first reported in 1905 by Codivilla.[1] He described 26 patients with lower limb deformities to which he applied 25 to 75 kg of distracting force through a plaster cast. After releasing the cast, additional force was applied such that 3 to 8 cm of limb lengthening was achieved in 20 to 35 days of distraction.

In the 1950's, the Russian orthopedic surgeon Gavriil Ilizarov popularized the technique and engaged in clinical and experimental research that resulted in the fundamental principles of DO.[2] These include minimal damage to the bone by low energy corticotomy, a latency period of 5-7 days, distraction rate of 1 mm/day, a rhythm of 2 activations of the device per day, and neutral fixation following the distraction period equal to twice the number of days of distraction. Aronson and colleagues have further advanced DO research in the canine tibia.[3]

Although the first uses of DO were to elongate bones, the procedure has been modified to augment deficient bone mass or discontinuities by a technique known as bone transport, or bi-focal DO. In this case, a segment of bone, called the "transport disc," is released and guided towards the other side

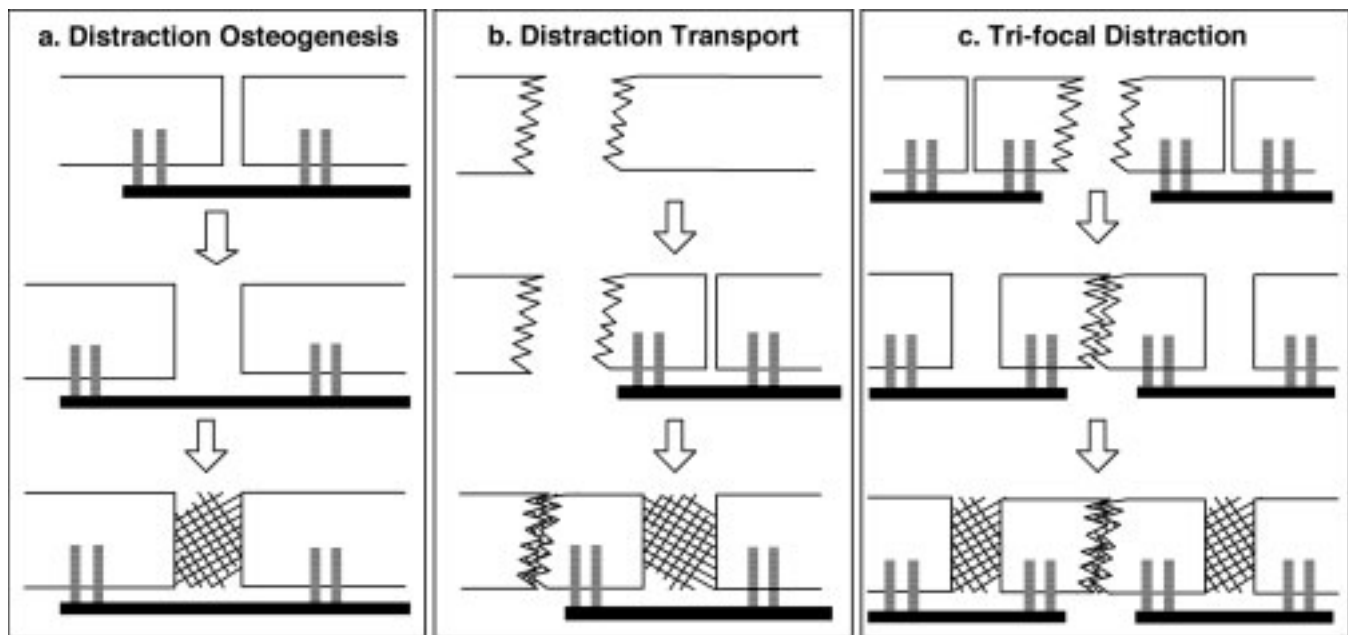


Figure 1. a: Distraction osteogenesis. b: Transport or bi-focal osteogenesis. c: Tri-focal distraction osteogenesis.

Dr. Julie Glowacki is Director of the Skeletal Biology Laboratory, Brigham and Women's Hospital and Professor of Orthopedic Surgery, Harvard Medical School and Professor of Oral and Maxillofacial Surgery, Harvard School of Dental Medicine.

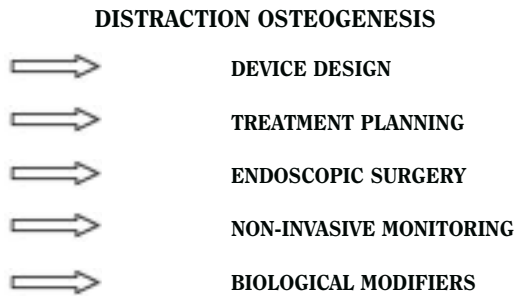
Please address correspondence to:

Julie Glowacki, Ph.D.
Brigham and Women's Hospital
75 Francis Street
Boston, MA 02125
Phone (617)732-5397
Fax (617)732-6937
jglowacki@rics.bwh.harvard.edu

of the defect, known as the "docking site," whilst bone fills the distracted gap and fusion occurs at the other side (Figure 1b). Tri-focal DO involves the transport of two opposing segments into a large void (Figure 1c). These techniques have been used for reconstruction of large segmental defects following trauma or surgical treatment of tumors.

In 1973, Snyder *et al.* were the first to report DO in the craniomaxillofacial region in dogs.[4] In 1992, McCarthy *et al.*

Figure 2. Multidisciplinary Program for Research in Distraction Osteogenesis



were the first to report mandibular DO in humans.[5] DO is especially attractive for children with congenital deficiencies or deformities. With Professor Leonard B. Kaban, D.M.D., M.D., Chief of Oral and Maxillofacial Surgery at the Massachusetts General Hospital, a multidisciplinary team of investigators developed a program of DO research that focuses on the anatomically complex mandible (Figure 2). The Yucatan minipig was selected as the experimental model because its mandibular size, anatomy, and function are very similar to those of the human mandible.[6,7,8,9]

DEVICE DESIGN

A significant requirement for the ultimate craniofacial device is a means of avoiding the problem of scarring of facial skin along the pin tracks as occurs with external distraction devices. Second, although unidirectional vectors, or trajectories, of elongation are needed in orthopedic applications of DO, more complex movements are required for craniomaxillofacial reconstruction. External, adjustable, bi-directional devices have been used when bone lengthening is required in both vertical and horizontal directions. Such complex movements, however, can be simplified as a family of curvilinear ones and have led to the design and testing of small, semi-buried “rack and worm-gear” devices capable of movement along fixed arcs.[10] Other goals are to have the device driven by a mini-motor capable of continuous advancements and to have at least the footplate/fixator manufactured from bioresorbable material.

TREATMENT PLANNING

Use of distraction for complex bones, such as the mandible, requires precise identification of the linear or curvilinear trajectory or multiple trajectories needed in order to achieve the desired result. Conventional two-dimensional radiographs and models have been used to plan treatment. Three-dimensional computed tomographic (CT) scans can aid the surgeon in planning the position of the distraction device, location of the osteotomy(ies), and amount of elongation, but specialized software can improve surgical planning and monitoring. With the BWH Surgical Planning Laboratory, software “tools” were developed to simulate “cutting” the bone and “moving” the segment to the desired position.[11] This innovative system defines landmarks, indicates skeletal interference, identifies the angles of the osteotomy and trajectory, and may potentially be incorporated into a surgical navigation system.

Effect of Fixation Time on Ultrasound Beam Penetration Depth (2 pigs at each rate)

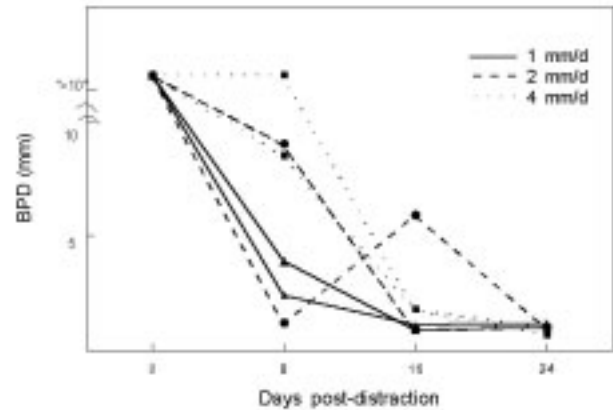


Figure 3. Non-invasive monitoring of ossification following mandibular distraction in minipigs. Ultrasonography was used to estimate the beam penetration depth (BPD) in the center of the distracted site. Duplicate hemi-mandibles were distracted at different rates, to a final advancement of 12 mm. Although the bones that were distracted at the slowest rate ossified earlier, BPD reached the value of intact bone in all specimens by 24 days. (Data redrawn from Thurmuller P *et al.* 2002.)

MINIMALLY INVASIVE SURGERY

Advances in miniaturizing devices and designing them to be buried and affixed directly to the bone have raised the potential for minimally invasive surgical approaches in DO. Drs. Troulis and Kaban have shown the feasibility, speed, and safety of using endoscopic instruments and techniques for a variety of reconstructive jaw procedures.[12, 13]

NON-INVASIVE MONITORING

Experimental DO wounds have been evaluated by clinical examination, plain radiographs, computed tomography, histology, molecular, and biomechanical assessment. It would be useful to have a reliable non-invasive monitor to indicate when rigid fixation is no longer required. Ultrasonography (US) and ultrasonometry have potential for clinical use, if they can be validated to correlate with bone healing. In a minipig study, US beam penetration depth reached normal levels at longer fixation times (Figure 3), in agreement with radiographic bone fill.[14]

BIOLOGICAL

Ossification following gradual distraction has been shown to be membranous,[2,3,6,7,15] *i.e.*, without significant production of cartilage, unless there is excess motion during the process. It is likely that ossification is so vigorous because neovascularization occurs concomitantly with distraction. We sought a way to examine the role of angiogenesis in bone formation, considering nicotine as a means of inhibition. In a novel rat mandible model, administration of nicotine significantly inhibited ossification (75%) and bone lengthening (49%).[16] This model provides the opportunity to define the relationship between osteogenesis and angiogenesis, and to evaluate potential means of enhancing impaired osteogenesis.

CONCLUSION

Available techniques for skeletal expansion are autogenous bone grafting, use of allogeneic banked implants or bone substitute materials, insertion of space-filling supporting devices, and mechanical or biological stimulation of bone formation. Current thinking about biological or “reparative medicine” emphasizes the potential to stimulate, enhance, or control a tissue’s innate capacity for repair. Distraction osteogenesis (DO) has become a commonly used technique for skeletal expansion, and multidisciplinary programs are needed to integrate the various aspects of its use for complex applications.

ACKNOWLEDGEMENTS

Aspects of this research program was supported by grants from the AO-ASIF Foundation, Switzerland, Partners CIMIT, and the Department of Oral & Maxillofacial Surgery Research Fund.

References

1. **Codivilla A.** On the means of lengthening, in the lower limbs, the muscles and tissues which are shortened through deformity. *Am J Orthop Surg.* 1905;2: 353-369.
2. **Iizarov GA.** The principles of the Iizarov method. *Bull Hosp Joint Dis Orthop Ins.* 1988;48: 1-11.
3. **Aronson J.** Experimental assessment of bone regenerate quality during distraction osteogenesis. In: *Bone Formation and Repair*, Brighton CT, Friedlaender GE, Lane JM (Eds), Am Acad Orthop Surgeons, Rosemont, IL. 1994; pp. 441-463.
4. **Snyder CC, Levine GA, Swanson HM, Browne EZ.** Mandibular lengthening by gradual distraction: A preliminary report. *Plast Reconstr Surg.* 1973;51: 506-508.
5. **McCarthy JG, Schreiber JS, Karp N, et al.** Lengthening of the human mandible by gradual distraction. *Plast Reconstr Surg.* 1992;89:1-8.
6. **Troulis MJ, Glowacki J, Perrott DH, Kaban LB.** Effects of latency and rate on bone formation in a porcine mandibular distraction model. *J Oral Maxillofac Surg* 2000;58:507-513.
7. **Glowacki J, Shusterman EM, Troulis M, Holmes R, Perrott D, Kaban LB.** Distraction osteogenesis of the porcine mandible: Histomorphometric evaluation of bone. *Plast Reconstr Surg.* In Press.
8. **Castano FJ, Troulis MJ, Glowacki J, Kaban LB, Yates KE.** Proliferation of masseter myocytes after distraction osteogenesis of the porcine mandible. *J Oral Maxillofac Surg.* 2001;59: 302-307.
9. **Kaban LB, Thurmuller P, Troulis MJ, Glowacki J, Wahl D, Linke B, Rahn B, Perrott DH.** Correlation of biomechanical stiffness with plain radiographic and ultrasound data in an experimental mandibular distraction wound. *Int J Oral Maxillofac Surg.* In Press.
10. **Seldin EB, Troulis MJ, Kaban LB.** Evaluation of a semiburied, fixed-trajectory, curvilinear, distraction device in an animal model. *J Oral Maxillofac Surg.* 1999;57:1442-6.
11. **Troulis MJ, Everett P, Seldin EB, Kikinis R, Kaban LB.** Development of a three-dimensional treatment planning system based upon computed tomographic data. *Int J Maxillofac Surg.* 2002;31:349-57.
12. **Troulis MJ, Perrott DH, Kaban LB.** Endoscopic mandibular osteotomy, and placement and activation of a semiburied distractor. *J Oral Maxillofac Surg.* 1999;57:1110-13.
13. **Troulis MJ, Kaban LB.** Endoscopic approach to the ramus/condyle unit: Clinical applications. *J Oral Maxillofac Surg.* 2001;59:503-9.
14. **Thurmuller P, Troulis M, O’Neill MJ, Kaban LB.** Use of ultrasound to assess healing of a mandibular distraction wound. *J Oral Maxillofac Surg.* 2002;60:1038-44.
15. **Yates KE, Troulis MJ, Kaban LB, Glowacki J.** IGF-I, TGF- β , BMP-4 are expressed during distraction osteogenesis of the pig mandible. *Int J Oral Maxillofac Surg.* 2002; 31:173-178.
16. **Schulten AJM, Kaban LB, Perrott D, Glowacki J.** Effect of nicotine on distraction osteogenesis of the rat mandible. *J Bone Min Res.* 2002;17:S243.