Metacarpophalangeal Arthroplasty in Rheumatoid Arthritis

Philip E. Blazar, M.D.
Department of Orthopaedics, Brigham and Women's Hospital, Boston MA

INTRODUCTION

Metacarpophalangeal (MP) arthroplasty is the most common and successful joint replacement surgery of the hand. This paper will briefly review the anatomy of the MP joint, and the indications, technique, results and complications of MP arthroplasty. Although MP implants are occasionally performed for post-traumatic or osteoarthritic joints, the literature focuses on patients with rheumatoid or other inflammatory arthritides. These patients can anticipate deformity correction, improved function and highly effective pain relief.

The hand is the primary mode of interaction with our environment. Therefore, even minor alterations of hand and wrist function resulting from rheumatoid arthritis (RA) affect the ability to function occupationally, recreationally and in activities of daily life. A multidisciplinary approach involving the rheumatologist, hand surgeon, and hand therapist is advisable in caring for these patients. Because delays in surgical and non-surgical treatment may lead to further disease progression, joint destruction and loss of function, early intervention is imperative. The initial evaluation and subsequent treatment of each patient's problem are challenging because of the anatomic complexities of the hand and wrist. However, a strong understanding of the relevant anatomy and a systematic approach to patient evaluation allow a logical plan of treatment to be generated.

ANATOMY

The normal MP joint is a diarthodial, condylar-type joint. The metacarpal head has a greater surface area than the base of the proximal phalanx. The articular surface of the head is convex and has a wider volar surface. The asymmetry of this surface accounts for the tightening of the collateral ligaments when the joint is brought into flexion. This asymmetry also results in a mobile center of rotation to the MP joint, which moves volarly with flexion. The normal synovial membrane of the MP joint is attached around the margins of the articular cartilage with volar and dorsal capsular reflections. The largest synovial fold is found on the dorsal neck of the metacarpal. (10)

The arc of motion of the normal MP joint is described as neutral to 90 degrees of flexion, although many individuals will demonstrate variable degrees of hyperextension. Radial and ulnar deviation is maximized in extension and is decreased with flexion and the associated tightening of the collateral ligaments. The MP joint deviates slightly in the ulnar direction with flexion of the digits.

The joint is stabilized by ligamentous structures. The collateral ligaments originate on the dorsal aspect of the metacarpal head - neck junction and insert on the volar aspect of the proximal phalanx. The collaterals are the primary stabilizers against varus-valgus and dorsal-palmar stresses. The volar plate has a membranous attachment on the neck of the metacarpal and a more fibrous attachment on the base of the proximal phalanx; it acts as the primary stabilizer against hyperextension. The flexor tendon sheath, the intermetacarpal ligaments and the sagittal bands of the extensor hood attach to the volar plate. The accessory collateral ligaments are located volar to the collateral ligaments and insert into the volar plate; they act as stabilizers of the volar plate, as well as secondary stabilizers against varus-valgus stress.

The interossei and lumbrical muscles exert a flexion force on the MP joint through their attachments into the extensor hood and proximal phalanx. The sagittal bands aid in extension of the MP joint through their insertion into the volar plate, as well as stabilizing the extensor tendons over the joint itself. The long flexor tendons can exert a flexion moment on the MP joint but their insertions on the distal and middle phalanges require this to occur after interphalangeal joint flexion.

PATHOPHYSIOLOGY OF RHEUMATOID MP JOINTS

The MP joint is the most common site of involvement in RA. Destruction of the MP joint in RA begins with a proliferative synovitis and progressively leads to a volarly subluxated proximal phalanx with ulnar deviation and destruction of the articular cartilage. MP joint deformities in RA have been extensively described. Characteristic changes occur in the articular surface, soft tissue stabilizing structures and bony supports. (10,16)

The primary causative factor producing the MP joint deformities characteristic of RA remains controversial. Zancolli and others have proposed a dynamic deformity, which exists prior to articular destruction. (22) Inflammation of the carpometacarpal joints exaggerates the spread of the metacarpals and

Please address correspondence to:

Philip E. Blazar, M.D.
Assistant Professor in Orthopedic Surgery
Harvard Medical School
Attending Physician, Department of Orthopaedic Surgery
Brigham and Women's Hospital
75 Francis Street
Boston, MA 02115
(617) 732-8550
pblazar@partners.org

the tendency for the MP joints to move into ulnar deviation with flexion. The supination deformity of the carpus leads to a radial deviation of the metacarpals. The resulting imbalance of forces on the extensor tendons results in their subluxation off the metacarpal head. This is facilitated by synovial infiltration along the collateral ligaments and at their attachments, which results in stretching out of the radial ligaments, producing further ulnar deviation and subluxation. The synovial proliferation within the joint contributes to attenuation of the radial sagittal bands and facilitates migration of the extensor tendons. (10,16)

The theory of a dynamic deformity preceding the development of MP articular changes is not universally accepted, and some authors feel that changes in the articular surface are primary. The initial changes seen in articular cartilage are softening and a loss of normal translucent appearance. A gradual progression to fibrillation and pitting of the surface of the metacarpal head occurs, followed by erosions and exposed bone. Bony erosions correspond to areas of synovial reflection. Volar erosions tend to be shallower than dorsal ones. Erosions in any area have the potential to penetrate through the cortical bone, although this is less common volarly. In advanced cases, the erosions can coalesce circumferentially around the metacarpal neck. Erosions of the proximal phalanx occur later in the disease and tend to involve a circumferential margin around the base of the phalanx. (10)

The capsular laxity of the MP joints that allows radial-ulnar deviation and flexion-extension motion makes subluxation/dislocation common sequelae of synovitis. When capsular laxity is combined with extensor tendon subluxation, joint deformity progressively leads to a fixed, volarly subluxated proximal phalanx with ulnar deviation. Attempts at finger extension lead to ulnar deviation. Additional ulnar deviation forces come from deformity of the wrist and tenosynovitis of the flexor tendons resulting in ulnar displacement of the flexors. With progressive subluxation the radial sided structures stretch and the ulnar ligaments and intrinsic muscles shorten. The fixed flexion deformities result in the inability to open the hand to grasp large objects and difficulty in fine manipulation of objects between the index and long fingers and the thumb.

Nalebuff and Millender have classified deformity of the MP joint in RA. (11) Stage I disease is characterized by MP synovitis with the ability to fully extend the joint, and little ulnar deviation or articular changes. Patients are managed medically for the synovitis, with splinting and/or corticosteroid injections for symptomatic relief. Night splints that hold the MP joints in extension and correct ulnar deviation are frequently prescribed.

Stage II is marked by the development of early erosions. Pain is generally the chief complaint. The extensor tendons show a tendency to move towards the web spaces. An extensor lag commonly exists, but flexion is well preserved. Clinical intervention focuses on maximizing medical management. Surgical intervention is infrequently performed, but could include synovectomy and soft tissue balancing. Synovectomy is not thought to alter the long-term prognosis of the disease but is widely accepted for alleviating local symptoms. Prior to undertaking soft tissue realignment, the surgeon must consider the adjacent joints and the mechanical effects on the MP. The incision for a Stage II procedure is the same as that utilized for arthroplasty should further surgery be necessary. Some surgeons consider crossed intrinsic transfers to the radial lateral band for significant ulnar deviation.

Stage III disease is characterized by advancing joint destruction and increasing deformity. These patients frequently have substantial PIP disease. The surgical decision is whether arthroplasty or tendon centralization and synovectomy is appropriate. The patient's level of pain and the function of the affected hand typically guide this decision.

Stage IV disease is marked by fixed subluxation and destruction as seen on radiographs. By this stage, silicone implants are widely considered the treatment of choice, and decision-making focuses on the options available for the other joints. However, in a young patient with a functional range of motion of the MP joint (an active arc of motion of 60 to 70 degrees), the surgeon must determine whether surgical intervention is indicated, as there is unlikely to be functional improvement. Examination of the wrist and PIP joints must be performed, as changes in these areas are more common with advanced disease and may need to be surgically addressed prior to performing an MP arthroplasty. (3,16)

PATIENT EVALUATION

Evaluation of the rheumatoid patient with involvement of the MP joints requires an assessment of the global function of the extremity and in particular any deformities of adjacent joints. Adjacent joint deformity and subsequent progression may contribute to the ultimate success or failure of any procedure performed in the MP joints. Progressive deformity of the wrist, in particular, may predispose MP arthroplasty to early recurrent ulnar deviation. A systematic framework, which divides the hand and wrist into four anatomic regions, should be followed in examining a deformed hand and wrist. First, the wrist should be evaluated for localized areas of pain, tenderness and swelling indicative of synovitis or tenosynovitis. Changes in range of motion over time are important when evaluating disease progression. Next, the thumb joints--carpometacarpal (CMC), metacarpophalangeal (MP), and interphalangeal (IP)-- are examined. Deformity and active and passive ranges of motion are all checked. Third, the index through small fingers are evaluated for swelling, deformity and range of motion at the MP joint. Lastly, the proximal interphalangeal (PIP) and distal interphalangeal (DIP) joints are assessed for articular destruction and tendon imbalance. (Figure 1)

Figure 1: Deformities of the digits. The index finger has a Boutonierre deformity while the middle finger has a swan neck deformity.

TREATMENT OPTIONS

Rest, exercise, splinting and corticosteroid injections play a critical role during early and late stages of the disease. Inflamed, painful joints will commonly respond to rest to diminish acute synovitis. Diseased joints require use to prevent worsening contractures, as active motion is needed to maintain tendon gliding and muscle tone. In general, short frequent periods of exercise are preferable to longer periods that have the potential to aggravate existing inflammation. A hand therapist is invaluable to achieve the appropriate balance and monitor activity.

Patients are commonly treated with resting and dynamic splints. Resting splints are effective in relieving pain yet allow many functional activities. Dynamic splints provide slow, constant stretching to help alleviate deformity. Corticosteroid injections are utilized to lessen synovitis and tenosynovitis and are commonly used for carpal tunnel syndrome, extensor tenosynovitis and for individual joints refractory to medical treatment. While serious complications are uncommon, tendon ruptures may be caused by frequent or repeated steroid administration. Thus, steroid injections should be limited to two or three times annually. Any joint or tendon sheath in the hand with synovitis prompting repeated steroid injection may benefit from surgical intervention.

The history of MP joint replacement is heavily dependent upon the work of Albert Swanson, which was first reported in 1966. (17) The silicone rubber implants used in MP arthroplasty differ in their fixation, articulation and motion from the prostheses commonly used in larger joints. The role of the implant, according to Swanson, is not to function as a true prosthesis, but to serve as a spacer to maintain the joint in alignment after a resection arthroplasty is performed. (18) The implant provides enough stability in the early post-operative period to mobilize the joint. However, the contribution of the implant to joint motion is debated. These prostheses have been described as "dynamic spacers." (18) The implant promotes the development of a fibrous capsule, adapted to a functional range of motion determined by the post-operative mobilization. Swanson has termed the development of this fibrous capsule the "encapsulation process." (18)

Silastic MP implants are inserted without an attempt to achieve rigid fixation. The encapsulation process itself is the definitive fixation of the implant. A small amount of pistoning of the intramedullary stem of the implant occurs. (3) Attempts at more rigid fixation of these implants have resulted in early fracture and clinical failures. The pistoning or gliding of the implant within the medullary canal adds to the range of motion achieved by the arthroplasty, in addition to dispersing the forces of motion along the implant-bone interface. (16,18)

SURGICAL TECHNIQUE

The technique for MP arthroplasty has been extensively described. (2,4,5,8,18) A dorsal transverse incision is used at the level of metacarpal head-neck junction. The dorsal veins are preserved to the extent possible. The extensor mechanism is exposed and a longitudinal incision is made in the extensor hood. Swanson and most other authors make this incision through the attenuated ulnar sagital band, although Beckenbaugh and Lindscheid recommend preserving the ulnar hood if possible and incising the radial aspect of the extensor mechanism. (3,18) The capsule is then incised longitudinally and the neck of the metacarpal is exposed. A soft tissue release is necessary to relocate the phalanx and to allow preparation of the bony structures for insertion of the component. The collateral ligaments are released at their origin and the contracted ulnar intrinsics, including the abductor digiti minimi, are released. The flexor digiti minimi is preserved, as the small finger typically has the most difficulty achieving active flexion post-operatively. Some surgeons prefer not to release the ulnar intrinsic to the index finger in an attempt to preserve the function of the first palmar interosseous muscle for pulp to pulp pinch.

The metacarpal head is then removed along with capsular attachments after transecting the neck with a saw, rongeur or drill. The level of resection is just distal to the origin of the now reflected collateral ligaments. Hypertrophic synovium within the joint capsule is then removed. (3,18) Preparation of the medullary canal of the metacarpal is performed with hand reamers. Swanson uses a specially designed burr with a smooth tip to lessen the chance of cortical perforation. There is evidence that over-reaming of the canal is associated with periprosthetic bone loss post-operatively; therefore, reaming is minimized in both the metacarpal and proximal phalanx. After reaming, a trial prosthesis is selected. An effort is made to fit the largest size without applying undue force. An appropriately sized prosthesis should fit snugly while the transverse midportion of the implant rests against the cut surface of the bone. (18)

The proximal phalanx is prepared by making a perforation in the subchondral bone in line with the center of the medullary canal. The hole is enlarged to accept a rectangular prosthesis with a rasp or burr. The index finger may be held in a slightly supinated position while rasping to improve tip pinch. After preparation and reaming of the selected, trial prostheses are once again inserted to ensure proper fit. With placement of a properly sized trial, no subluxation of the joint should occurr and the implant should fit snugly into both canals. (18)

To improve the durability of the implants, some authors have suggested the use of implants with titanium grommets. In theory, the titanium protects from silastic wear. However, there is little clinical data documenting any benefit, and the data from animal experiments is inconclusive. (13) Some surgeons reserve the use of grommets for cases with extensive erosion of the dorsal aspect of the proximal phalanx to achieve a more stable construct.

Prior to insertion of the actual prosthesis, soft tissue reconstruction of the radial ligament complex must be considered. This is accomplished with the proper collateral ligament, unless it is severely attenuated. It is reattached with non-absorbable suture through holes in the metacarpal neck and imbricated as necessary. If the collateral ligament is deficient, an alternative radial ligamentous reconstruction has been

described with the volar capsule and half of the volar plate attached to the origin of the collateral ligament. (3,16,18) Kirschenbaum and Schneider have described good long-term results without a radial reconstruction. (Figure 4)

Figure 4: Typical appearance at implantation of four MP arthroplasties with Silastic implants.

The bony surfaces are then irrigated and prepared for implantation. A so-called "no-touch" technique is used with smooth forceps so as not to injure the surface of the silicone rubber, as implant fracture has been related to propagation of surface defects. The implant is first inserted into the metacarpal and then with flexion and distraction the distal end is placed into the phalanx. The radial reconstruction is tied down after placement of the implant, and the capsule is closed. The extensor tendon is centralized and the radial sagittal bands are reefed. The skin is closed with interrupted sutures over a subcutaneous drain. A bulky dressing is applied and the hand is splinted with the MP joints in extension to protect the soft tissue reconstruction. (16,18)

REHABILITATION

The traditional post-operative therapy protocol begins within one week of surgery. The patient is fitted with a dynamic splint holding the MP joints in extension and neutral to radial deviation. A static resting splint is also fabricated. The patient is encouraged to actively flex the MP joints in a controlled fashion to protect the extensor realignment and prevent prosthetic dislocation. The patient is weaned from the dynamic splint at six weeks post-operatively but static splinting is continued at night for three to four months. (20).

An alternative postoperative protocol has recently been proposed. (14) The patients are placed in a hand-based cast with the MP joints in extension and 10-15 degrees of radial deviation. The wrist and distal joints are left free. The cast is removed after 5 weeks and patients are begun in a therapy program of active and passive motion with a static nighttime splint for an additional six weeks. This protocol has demonstrated comparable results in one large series from a single surgeon and offers a much simpler rehabilitation protocol for patients and therapists.

RESULTS AND COMPLICATIONS

The silastic implants used in MP arthroplasty function differently than those used in the more common large joint replacements. MP silastic arthroplasties are not fixed to the skeleton and patients have motion between the implant and the bones as well as within the implant. Attempts at engineering MP arthroplasties similar to larger joint replacements continue, but they are not widely accepted at this time. The literature on these MP total joint replacements is limited and demonstrates results that are not convincingly superior to silastic arthropasty for most patients with RA. In addition, dislocation of these less constrained implants can occur as a result of the extensive soft tissue attenuation/destruction in RA.

The results after MP silastic arthroplasty are well-documented. Overall, function is substantially improved in appropriately selected patients. The variables reported in the literature include range of motion, ulnar deviation, pain relief and patient satisfaction. Realistic expectations are important, as the arthroplasties are not expected to achieve a full range of MP motion. Patients with substantial extensor lag or ulnar deviation preoperatively will only have a small increase in the arc of motion, but the arc will be in a more functional position. Key and tip pinch will also be improved as the index is brought over into a radial position. Reported post-operative arcs of motion vary from 38 to 60 degrees. (1,2,4,5,7,8,18) Extension lags also vary from 9 to 22 degrees. (1,2,4,5,7,8,18) Loss of motion over time also may occur, as Bierber reported a loss of 12 degrees of active motion at an average of 5 years of follow-up (4)

Ulnar deviation is reliably corrected, although there is a tendency for some ulnar drift to recur with long-term follow-up. The correction of deformity has been documented as one of the major contributors to patients' subjective sense of improvement. Correction within a few degrees of neutral is reported in most series. Recurrent ulnar drift has been reported in up to 43% of patients, however, the recurrent deformities reported is less than 20-30 degrees in most series. (1,2,4,5,7,8,18)

Pain relief is inconsistently documented in follow-up studies of MP arthroplasty, although clinical experience suggests that it is consistent. Kirschenbaum reported that of 144 arthroplasties in 36 hands, none complained of pain. Bieber reported that only 20% of patients in their series reported pain as a pre-operative concern. (4,8) Beckenbaugh reported recurrence of pain in 2 percent of patients at an average follow-up of 32 months. (2) Patient satisfaction with the procedure is generally high, with the majority of patients in most series reporting they would undergo the procedure again.

The patient's subjective appraisal of outcome has been investigated for its relationship to deformity, strength, range of motion, pain relief and other traditional parameters of success. Notably, the strongest determinant of patient satisfaction was with appearance and correction of deformity. Pain relief was also found to be important, but the other traditionally examined

Figure 2: Photograph demonstrating changes in appearance before (right hand) and after MP arthroplasty (left hand).

parameters (motion, strength etc.) were not found to have a statistical correlation. (9) (Figure 2)

Silicone rubber MP joint implants generally have a low rate of complications. (1,2,4,5,7,18) Several other types of MP prostheses have a higher rate of long-term complications. (1) Foliart has published an extensive review of the literature on complications of Swanson finger joint implants. (7) The most frequently reported complication was extensive change in the bone surrounding the implant. This complication was found in 4% of silicone rubber implants. (7) Swanson has extensively studied the changes in bone morphology. (19) Metacarpal mid-shaft cortical bone consistently decreased post-operatively in this study, and the length of metacarpals with implants in place decreased by an average of 9%. (19) Bones remodeling also resulted in thickening of the bony surfaces at the metacarpal and phalangeal metaphysis while maintaining the shape of the cut end of the metacarpal. (19)

Foliart found implant fracture in 2% of reported cases. (7) However, the rate of implant fracture varies form 0% (4) to 38% (2) and may depend on how extensively the investigator looks for radiographic evidence of fracture. (1,2,4,5,8,18) Many authors report that the majority of patients with fractured implants have acceptable function and do not require revision. The low morbidity of fractured prosthesis has been related to the function of the implant as a spacer rather than as an articulated prosthesis. (1,2,4,5,8,18) Several changes have been made in the implants to address this problem. The originally used silicone rubber 372 has been replaced by "high performance" (HP) silicone rubber. In vitro investigation demonstrates improved resistance to fracture and tear propagation with the newer silastic. Studies of HP implants only have shown fewer fractures when compared to historical studies, although to our knowledge no controlled trials have been undertaken to evaluate this. (Figure 3)

Infection was noted in 0.6% of reported implants by Foliart. (7) Most series, including Swanson's, report a rate between 0.1 and 1%. (1,2,4,5,8,12,18) Millender and Nalebuff have published a detailed report on infection after silicone arthroplasty in the hand. All of Millender's infections presented within 8 weeks of implantation. Staphylococcus Aureus was the most common organism isolated and most of the prostheses ultimately required removal, and an average of two weeks of antibiotic treatment. (12)



Figure 3: Fractured silastic implant retrieved at 1 year from implantation.

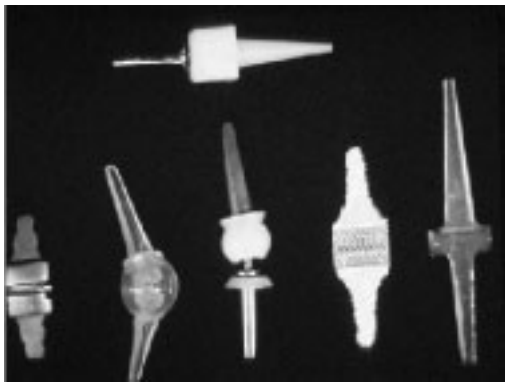

Figure 6: A number of the MP implants at use at different times. The far right is the most widely used implant designed by Swanson.

Figure 5: A. Pyrolytic Carbon articulated MP prostheis being marketed by Ascension Orthopaedics.

Figure 5: B. Post-operative radiograph after MP arthroplasty using the pyrolytic carbon prosthesis.

Particulate synovitis and silicone induce lymphadenopathy have received substantial attention. Both of these complications were recorded in less than 0.1% of reported cases by Foliart. (7) Synovitis in MP implants occurred almost exclusively in fractured implants or in implants with substantial signs of wear at removal. Four patients with lymphadenopathy and silicone rubber implants have been reported who developed non-Hodgkin's lymphoma. All four were in rheumatoid patients with a concomitant 10-fold increased risk over the general population of developing lymphoma. (7).

ALTERNATIVE IMPLANTS

A variety of alternatives to silastic flexible implants have been proposed in the more than 30 years since they came in widespread use, but none have gained wide acceptance. (Figure 6) Current alternatives include implant designs more analogous to joint replacements used in larger joints. (Figure 5A and B) Specific differences from silastic arthroplasty include rigid fixation and the use of two distinct components. There are currently both cemented and cementless components available on the market. While these implant have been implanted and evaluated to a certain degree in the literature, further investigation is warranted to establish the indications, contraindications, results and longevity of these types of implants in relation to silastic MP arthroplasty for patients with RA.

SUMMARY

Treatment of the arthritic rheumatoid MP joint requires consideration of the degree of compromise, as well as a thorough understanding of the anticipated outcome of the options for intervention. Silicone MP arthroplasty is one of the more successful operations performed in these patients when it is applied at the appropriate stage. The patient can anticipate a reversal of deformity, an active arc of motion of 40 to 50 degrees in a functional position and effective pain relief. Subjectively, patients report satisfaction with the correction of deformity and pain relief. Although MP arthroplasty is a successful procedure, problems do exist. Recurrence of a mild ulnar drift deformity occurs in a substantial percentage of patients. Implant fracture remains a concern, although the incidence of this problem has probably been reduced with the development of high performance silicone rubber. Longevity and reliable function beyond ten years has yet to be documented. Silicone arthroplasty provides an important method for the hand surgeon to improve the function of patients with severe MP disease. Future advances in implant technology and surgical technique will need to address existing problems to allow MP arthroplasty to become a more successful and widely applicable operation.

References

1. **Adams BD, Blair WF, Shurr DG.** Schultz Metcarpophalangeal Arthroplasty: A long-term follow-up study. J Hand Surg. 1990;15A: 641-645.
2. **Beckenbaugh RD, Dobyns JH, Linscheid RL, Bryan RS.** Review and Analysis of Silicone-Rubber Metacarpophalengeal Implants. J Bone Joint Surg 1976;58A:483-487.
3. **Beckenbaugh RD, Linscheid RL.** Arthroplasty in the Hand and Wrist. In: *Operative Hand Surgery*. DP Green (ed). Churchill Livingstone, New York, 1993;143-188.
4. **Bieber EJ, Weiland AJ, Volenec-Dowling S.** Silicone-Rubber Implant Arthroplasty of the Metacarpophalangeal Joints for Rheumatoid Arthritis. J Bone Joint Surg Am. 1986;68A:206-209.
5. **Blair WF, Shurr DG, Buckwalter JA.** Metacarpophalangeal Joint Implant Arthroplasty with a Silastic Spacer. J Bone Joint Surg Am. 1984;66A:365-370.
6. **Cook SD, Beckenbaugh RD, Redondo J, Popich LS, Klawitter JJ, Linscheid RL.** *Long-term follow-up of pyrolytic carbon metacarpophalangeal implants. J Bone Joint Surg Am* 1999;81A:635-48
7. **Foliart DE.** Swanson Silicone Finger Joint Implants: A Review of the Literature Regarding Long-term Complications. J Hand Surg Am. 1995;20A:445-449.
8. **Kirschenbaum D, Schneider L, Adams DC, Cody RP.** Arthroplasty of the Metacarpophalangeal Joints with Use of Silicone-Rubber Implants in Patients who Have Rheumatoid Arthritis. J Bone Joint Surg Am. 1993;75A:3-12.
9. **Mandl LA, Galvin DH, Bosch JP, Georgon CC, Simmons BP, Axt TS, Fossel AH, Katz JN.** Metacarpophalngeal arthroplasty in rheumatoid arthritis: what determines satisfaction with surgery?. Rheumatol. 2002 Dec 29(12)2488-91
10. **McMaster M.** The Natural History of the Rheumatoid Metacarpo-Phalangeal joint. J Bone Joint Surg Br. 1972;54B:687-697.
11. **Millender L, Nalebuff E.** Metacarpophalangeal Joint Arthroplasty Utilizing the Silicone Rubber Prosthesis. Orthop Clin North Am. 1973;4:349-371.
12. **Millender LH, Nalebuff EA, Hawkins RB, Ennis R.** Infection after Silicone Prosthetic Arthroplasty in the Hand. J Bone Joint Surg Am. 1975;57A:825-829.
13. **Minamikawa Y, Peimer CA, Ogawa R, Fujimoto K, Sherwin FS, Howard C.** Experimental analysis of silicone implants used with titanium grommets. J Hand Surg Am. 1994;19A:567-74.
14. **Patterson P, Simmons BP, Ring D, Earp B:** Static versus dynamic splinting and early motion after metacarpophalangeal arthroplasty. Presentated at 54th Annual Meeting of the American Society for Surgery of the Hand, September 1999, Boston, Massachusetts.
15. **Riordan DC, Fowler SB.** Arthroplasty of the Metacarpophalangeal Joints: Review of Resection-type Arthroplasty. J Hand Surg. 1989;14A:368-370.
16. **Stirrat CR.** Metacarpophalangeal Joints in Rheumatoid Arthritis of the Hand. Hand Clin. 1996;12:515-529.
17. **Swanson AB.** A Flexible Implant for Replacement of Arthritic or Destroyed Joints in the Hand. NYU Post-Graduate Medical School Inter-Clin Inform Bull. 1966;6:16-19.
18. **Swanson AB.** Flexible Implant Arthroplasty for Arthritic Finger Joints. J Bone Joint Surg Am. 1972;54A:435-455.
19. **Swanson AB, Poitevin LA, Swanson GDG, Kearney J.** Bone Remodeling Phenomena in flexible Implant Arthroplasty in the Metacarpophalengeal Joints. Clin Orthop. 1986;205:254-267.
20. **Swanson AB, Swanson GdG, Leonard JB.** Postoperative Rehabilitaion Programs in Flexible Implant Arthroplasty of the Digits. In: *Rehabilitation of the Hand: Surgery and Therapy*. JM Hunter (ed). Mosby, St. Louis. 1995;1351-1376.
21. **Tupper JW.** The Metacarpophalangeal Plate Arthroplasty. J Hand Surg Am. 1989;14A:371-375.
22. **Zancolli E.** Structural and Dynamic Bases of Hand Surgery. In: Philadelphia, JB Lippincott, pp 325-360, 1979