

# SUPERIOR LABRAL TEARS OF THE SHOULDER: SURGICAL REPAIR USING A BIORESORBABLE KNOTLESS SUTURE ANCHOR

CONRAD WANG, MD, EDWARD YIAN MD, PETER J. MILLETT MD, MSc., JON J.P. WARNER, MD

HARVARD SHOULDER SERVICE, DEPARTMENTS OF ORTHOPAEDICS AT MASSACHUSETTS GENERAL HOSPITAL AND BRIGHAM AND WOMEN'S HOSPITAL, BOSTON MA

## ABSTRACT

The diagnosis and treatment of superior labrum (SLAP) tears have improved with the development of arthroscopic shoulder surgery techniques. With tears involving detachment of the biceps anchor, the goal is to restore stability to the labrum and biceps anchor and achieve healing to the glenoid. Suture repair with anchors is currently the repair technique of choice. The purpose of this article is to review the classification, pathoanatomy and treatment of SLAP lesions, and to report a simple method for arthroscopic SLAP repair that uses knotless suture anchors and obviates the need for complex suture management and arthroscopic knot tying. We also present preliminary clinical results of isolated SLAP repairs in a general population.

## INTRODUCTION

The rapid evolution of arthroscopic shoulder surgery over the past decade has given orthopaedic surgeons the ability to treat many injuries utilizing arthroscopic techniques, with the goal of an anatomic repair. Andrews *et al.* first described superior labrum lesions in 1985<sup>1</sup>, and the acronym SLAP lesions (superior labrum anterior to posterior) and their classification was subsequently proposed by Snyder *et al.*<sup>2</sup> and further defined by Maffet *et al.*<sup>3</sup> Snyder described four types of lesions with increasing involvement of the biceps tendon.<sup>2</sup> Type I lesions are characterized by fraying of the superior labrum with an intact biceps anchor. Type II lesions represent detachment of the biceps anchor and superior labrum. Type III lesions are a bucket-handle tears of the superior labrum, with an intact biceps anchor insertion to bone. Type IV lesions are a bucket-handle tear of the superior labrum with extension into the biceps tendon. For types II and II, the currently preferred

treatment is surgical repair to restore stability to the biceps anchor. The true prevalence of SLAP lesions in shoulder injuries remains unknown, but reported values have ranged from 6% to 26% of all patients undergoing shoulder arthroscopy.<sup>4,5</sup>

SLAP lesions can often be debilitating, especially in the overhead athlete. Snyder *et al.* characterized his experience with over 140 lesions and reported that only 28% of SLAP lesions were an isolated entity.<sup>2</sup> More recently, Kim *et al.* reported that only 12% of 139 patients with SLAP lesions did not have associated pathology.<sup>4</sup> Associated lesions included partial and full thickness rotator cuff tears, Bankart lesions and acromioclavicular joint degenerative disease. However, the relationship between SLAP lesions and associated pathology has not yet been defined.

It has been suggested that the biceps and its attachment at the supraglenoid tubercle plays a role in shoulder stability. In experimental studies, the creation of a superior labrum lesion decreased the ability of the shoulder joint to resist external rotation when the shoulder was positioned in abduction and external rotation.<sup>6</sup> Selective cutting studies have demonstrated that release of both of the superior labrum and supraglenoid tubercle are required to produce significant laxity of the biceps tendon.<sup>7</sup> Electromyographic studies on activity of the long head of biceps in shoulder function have been conflicting, as Sakurai *et al.* have reported significant contraction of the long head of biceps in repetitive maximal isometric forward flexion and abduction,<sup>8</sup> but Yamaguchi *et al.* reported no activity in the long head of biceps with shoulder motion.<sup>9</sup>

Several explanations of the mechanism for superior labral injury have been suggested. Andrews *et al.* proposed that traction of the long head of biceps tendon "pulls" off the attached labrum.<sup>1</sup> Similarly, Maffet *et al.* proposed that traction injuries were the most common mechanism with an inferiorly directed force.<sup>3</sup> In contrast, Snyder *et al.* suggested that the most common mode of injury was a compressive mechanism from a forward fall, leading to a tear beginning posterior and extending anterior to the biceps anchor.<sup>2</sup>

Patients with SLAP lesions involving the biceps anchor that have persistent symptoms despite conservative management are candidates for surgical repair. Suture repair with anchors is widely advocated.<sup>2,10</sup> In experienced hands, arthroscopic knots can provide secure fixation. However, there is a significant learning curve associated with arthroscopic knot tying, and improper knot tying with sliding knots may be a potential cause of treatment failure and recurrent pain.

Conrad Wang, MD is a Resident in the Harvard Combined Orthopaedic Residency Program

Edward Yian, MD is a Fellow in Shoulder Surgery, Harvard Shoulder Service

Peter Millett, MD, MSc is a Clinical Instructor in Orthopedic Surgery, Harvard Medical School, and Attending Physician at Brigham and Women's Hospital

Jon J.P. Warner, MD is an Associate Professor of Orthopedic Surgery, Harvard Medical School, Attending Physician at Massachusetts General Hospital, and Chief of the Harvard Shoulder Service.

Please address reprint requests to:

Peter J. Millett, MD, MSc  
275 Cambridge Street, POB 403  
Boston, MA, 02114  
Telephone: 617-732-5793  
Fax: 617-724-3846  
Email: pmillett@partners.org

Bioabsorbable knotless suture anchors (BioKnotless anchor, Mitek, Norwood, MA) have been reported to provide a secure, low profile repair without the added complexities of arthroscopic knot tying. The knotless anchor consists of a polylactic acid body with two prongs and an attached, closed “anchor” loop of braided Panacryl™ suture.<sup>11</sup> A longer, open “utility” suture loop is threaded through the anchor loop and is used to pass the anchor loop through the injured soft tissue, by means of any of several suture passing devices. One strand of the anchor loop is then captured between the two prongs of the anchor and driven into the bone, thus pulling the injured soft tissue into the drill hole with it. The utility loop is then removed from the joint, leaving only the two arms of the anchor loop securing the tissue to bone. Advantages of the knotless anchor include a lower implant profile, a bioabsorbable implant, increased suture strength (two suture limbs) compared with simple sutures, and the potential for improved healing as the tissue is pulled into the drill hole rather than on top of the suture anchor. Benefits of the new technique also include secure, reliable fixation, no need for bulky, difficult knots, and a more efficient operation.

A multitude of arthroscopic repair techniques have been described with associated portal placements, suture passage devices and fixation equipment. O’Brien *et al.* have recently reported good results using a lateral trans-rotator cuff portal for suture anchor repair of SLAP lesions.<sup>12</sup> This article describes the authors’ preferred technique for the repair of unstable SLAP lesions with a bioabsorbable knotless suture anchor utilizing an accessory trans-rotator cuff lateral portal.

## OPERATIVE TECHNIQUE

### ANESTHESIA AND PATIENT POSITIONING:

Our preferred anesthetic is a long-acting regional interscalene nerve block. This provides intra-operative and post-operative analgesia, minimizes postoperative pain, and allows for fast-track recovery.

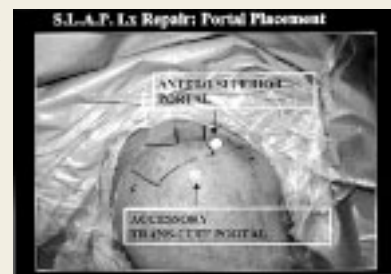A careful examination under anesthesia is performed to record passive range of motion and joint translation.

While repair of the superior labrum can be performed in the lateral decubitus position, we prefer the beach-chair position. This position allows easy access to the shoulder and facilitates the exposure for an open repair if the need should arise due to additional findings during arthroscopic evaluation. We utilize a surgical positioner (T-MAX positioner, Tenet Medical Engineering, Calgary, Canada) with a padded headrest in order to ensure adequate exposure of the posterior and lateral borders of the shoulder joint. It is important to keep the medial border of the scapula exposed and without interference from drapes. We have also had successfully utilized a set-up using a long beanbag on a standard surgical chair.<sup>13</sup> A pneumatic arm holder (The Spider, Tenet Medical Engineering, Calgary, Canada) is used to facilitate intraoperative positioning of the upper extremity.

### DIAGNOSTIC EXAMINATION:

Bony landmarks are identified and marked including the coracoid process, clavicle, acromioclavicular joint, acro-

**Figure 1.** Portal locations: A posterior camera portal, anterior superior portal and lateral trans-cuff working portal is established. (Reproduced from Yian *et al.*, 2003, with permission)



mion, and scapular spine. For introduction of the cannulae, the patient’s arm is placed in slight traction, 50 degrees of forward flexion and neutral rotation.

The skin is infiltrated with 0.25 % marcaine with epinephrine solution at the portal sites. The posterior portal is located 2 cm inferior and 1 cm medial to the posterolateral tip of the acromion (Figure 1). Saline solution is injected through the soft spot into the glenohumeral joint with careful attention to evaluate for back flow to prevent inadvertent infiltration of the capsular tissues. A 30-degree arthroscope is placed into the glenohumeral joint through the posterior portal to view the glenohumeral joint. An anterior portal is made via the “outside-in” approach with a spinal needle directed anterolateral to the AC joint through the rotator interval and inferior to the biceps tendon. A smooth, 5.5 mm x 70 mm cannula is inserted through this portal.

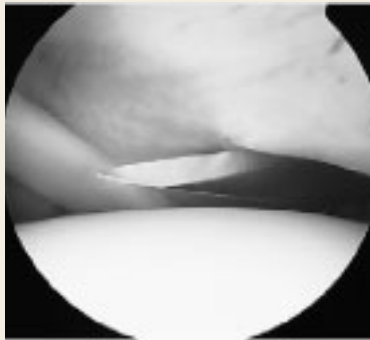
A complete, systematic arthroscopic examination of the glenohumeral joint is performed. Shoulder laxity is assessed with the arthroscopic anterior drawer test and drive-through sign. The quality of the capsular tissue and the degree of synovitis are also assessed. A probe is used to evaluate the stability of the labrum and biceps anchor. Recognition of the normal anatomic variants of the anterior labrum (sublabral foramen, Buford complex, or sulcus) is critical to unnecessary repair and postoperative stiffness or restriction of motion. Specifically, it is crucial to examine the undersurface of the labral attachment. Signs of injury included excessive laxity, fraying, partial detachment, tearing of insertional fibers, or elevation greater than 5 mm. The “normal” amount of laxity in the superior labrum is unknown and is probably extremely variable. Identification of labrum stability both anterior and posterior to the biceps anchor is important for proper accessory portal placement.

### LESION PREPARATION

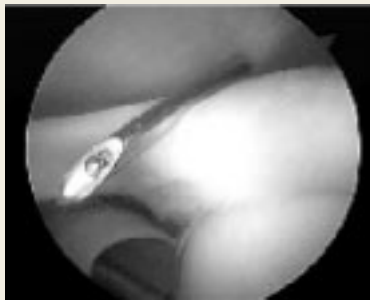After identification and classification of the SLAP lesion, a shaver is introduced through the anterior portal, and frayed or unstable labral tissue is debrided. For type I and type III SLAP lesions, no further treatment is indicated. Types II and type IV SLAP lesions are repaired. The superior rim of the glenoid is debrided free of soft tissue to expose a bony surface. At this point an accessory lateral trans-rotator cuff portal is created, 1-2 centimeters lateral to the acromion.

### TRANS-ROTATOR CUFF PORTAL PLACEMENT

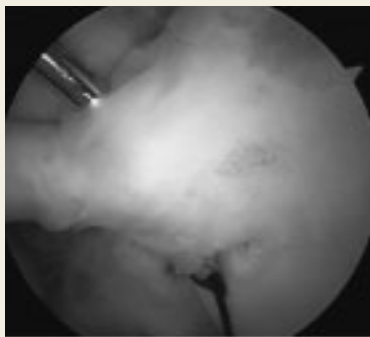
The arm is placed in maximal adduction in order to establish the portal through the proximal portion of the rotator cuff, away from its tendinous insertion. The optimum angle for the



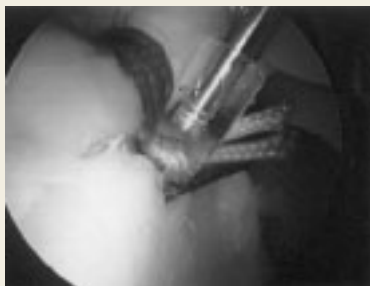**Figure 2.** Arthroscopic view, outside-in technique using spinal needle to establish optimal angle for trans-cuff portal, above biceps tendon. Note medial entry point, away from tendinous portion of rotator cuff. (Reproduced from Yian *et al*, 2003, with permission)



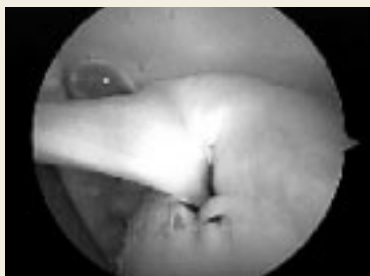**Figure 3.** Establishment of lateral trans-cuff portal. A #11 scalpel blade is inserted into the glenohumeral joint, longitudinally in line with rotator cuff fibers. (Reproduced from Yian *et al*, 2003, with permission)



**Figure 4.** Using the lateral trans-cuff portal, a straight suture hook is used to pass the wire suture passer under the torn labrum from superior to inferior, towards the glenoid. The wire suture passer is then used to pass the utility loop of the suture anchor under the labral tissue. (Reproduced from Yian *et al*, 2003, with permission)



**Figure 5.** The knotless suture anchor is introduced through the lateral trans-cuff portal, and is impacted into a previously drilled hole at the glenoid rim, after capturing one strand of the anchor loop. The depth of anchor insertion modulates tension of the repair, and one is able to visualize a “bumper” effect of gathered superior labral tissue. (Reproduced from Yian *et al*, 2003, with permission)



**Figure 6.** Repaired superior labrum with knotless suture anchor in place.

portal is first determined with a spinal needle, with the goal of directing the drill for the anchor at 45 degrees to the glenoid rim. For posterior tears, passage of the spinal needle through the supraspinatus or infraspinatus is necessary (Figure 2). A #11 scalpel blade is passed in line with the muscular fibers of the rotator cuff, under direct vision using the arthroscope (Figure 3). An entry portal measuring 5 millimeters is established. The arm may then be abducted for easier visualization of the rotator cuff tendinous insertion. It is important to stay as medial as possible, near the musculotendinous junction. A switching stick is used to enlarge the entry and a 5.5-mm x 70-mm smooth cannula is inserted over the rod.

#### REPAIR

A single 2.9-mm drill hole is made at the articular margin of the superior glenoid rim. Marking the location of the drill hole with radiofrequency cautery can simplify correct anchor placement. A suture hook (Spectrum Tissue Repair System, Linvatec Co., Largo, FL) is passed through the lateral portal to deliver a wire suture passer (Shuttle Relay, Linvatec Co., Largo, FL) through the superior labrum from superior to inferior, towards the glenoid. (Figure 4) The end of the suture passer is retrieved through the anterior portal. The suture hook is removed and the ends of the utility loop suture of the bioknotless anchor are loaded into the suture passer (outside of the lateral portal). Pulling the suture passer out through then anterior portal thus passes the utility loop through the superior labrum from superior to inferior. Alternatively, the utility loop can be passed through the superior labrum using a curved suture passer (Suture Lasso, Arthrex, Naples, FL). A larger, threaded 8.0-mm cannula is placed anteriorly through the rotator interval to accommodate the increased size of the curved suture passer. The curved suture passer is introduced through the anterior portal and passed through the superior labrum from inferior to superior, adjacent to the predrilled hole. An attached wire loop is then fed through the curved suture passer and retrieved through the lateral portal with a suture retriever. The free ends of the utility loop suture are placed through the wire loop. Removal of the curved suture passer from the anterior portal then passes the utility loop through the superior labrum from superior to inferior.

#### ANCHOR PASSAGE

Tension is maintained across the utility loop suture ends as the anchor is introduced into the joint from the lateral portal. After the anchor loop is pulled through the labral tissue by the utility loop, one strand of the anchor loop is captured under the anchor prongs and the anchor is driven into the previously marked drill hole until the loop is completely buried into bone (Figure 5). The depth of anchor insertion modulates tension of the repair, and one is able to visualize a “bumper” effect of gathered superior labral tissue. The repair is then probed to assess stability and the need for additional anchors (Figure 6). In our experience, a single anchor placed just posterior to the biceps anchor provides excellent stability of repair.

#### CLINICAL RESULTS

SLAP lesions have been reported as a significant source of

shoulder pain in overhead athletes, but less is known about the significance of isolated SLAP lesions in nonathletes. We have therefore reviewed the results of arthroscopic stabilization of isolated type II SLAP lesions in a general population.

Over a period of twenty months, 32 patients (25 male, 8 female) with isolated type II SLAP lesions were treated. Twenty injuries were in dominant shoulders. Mechanisms of injury were sports-related in five patients (weightlifting, tennis, diving, volleyball); trauma-related in five patients (motor vehicle collisions, falls from greater than standing height); due to falls from standing height in seven patients; and from repetitive injury or atraumatic in seven patients. Ten patients reported work-related injuries.

Early follow-up suggests that repair of isolated type II SLAP lesions is effective at returning patients to pre-injury work and sport levels, with two-thirds of patients returning to work at their previous level, and one-half of patients returning to sports at their previous level. While the numbers are small, there is also a suggestion that patients with work-related injuries may not fare as well after isolated SLAP repair. The most common complaint after surgery was persistent pain with overhead activity.

## DISCUSSION

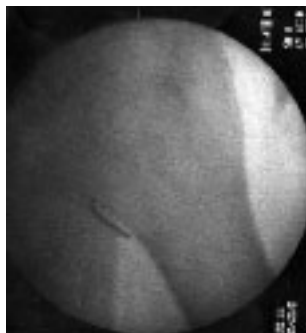
Knotless suture anchors can simplify the technique for arthroscopic SLAP repair and lead to a shorter operative time. However, potential pitfalls still exist, and are primarily technique-related. They include:

- Damage or transection of the labrum or biceps as the tear is debrided or the suture passer is used.
- Iatrogenic damage of the articular surface from slippage of the drill tip off the glenoid rim or incorrect angle placement. This can be prevented by using a spinal needle to assess an optimal approach angle before portal placement, as well as by using a drill guide or tapping on the drill handle before drilling the anchor hole.
- Injury to the rotator cuff if the scalpel blade is inserted too laterally, or obliquely to the fibers of the rotator cuff.
- Bending or breakage of the suture hook tip if an incorrect angle results in application of excessive force during attempted suture passage (Figures 7,8).
- Suture abrasion and improper fixation arising from twisting of the suture loop during anchor insertion.
- Improper fixation from impacting both limbs (instead of one limb) of the anchor suture loop into the drilled hole.
- Failure of the tissue through the suture loop arising from over impaction of the knotless anchor into bone.

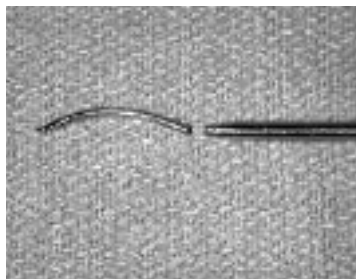
We have presented our technique for performing arthroscopic superior labrum repair using a bioabsorbable knotless suture anchor, which minimizes the need for complex suture management and arthroscopic knot tying. It is easily reproducible and appears to allow for a safe and stable repair. With careful examination and documentation, arthroscopic stabilization of symptomatic isolated superior labral detachment in a general population produces good results according to patient assessment of pain relief and shoulder function and patient satisfaction. Poorer results may be influenced by patient secondary gain. Further investigation of patient outcomes after isolated SLAP repair is currently being performed, in order to evaluate the longer-term efficacy of these repairs.

## ACKNOWLEDGEMENTS

Figures 1-7 reprinted from *Arthroscopy*, Yian E *et al.* "Technical Note: Arthroscopic Repair of SLAP Lesions with a Bioknotless Suture Anchor," (In Press), with permission from Elsevier.



**Figure 7.** Fluoroscan image of broken suture hook in shoulder joint. (Reproduced from Yian *et al.*, 2003, with permission)



**Figure 8.** Broken tip of suture hook, retrieved from glenohumeral joint.

## References

1. **Andrews JR, Carson WG, Mcleod, WD.** Glenoid labrum tears related to the long head of the biceps. *Am J Sports Med* 1985;13:338-341.
2. **Snyder SJ, Karzel RP, Del Pizzo W, Ferkel RD, Friedman MJ.** SLAP lesions of the shoulder. *Arthroscopy* 1990;6:274-279.
3. **Maffet, MW, Gartsman GM, Moseley, B.** Superior Labrum-Biceps Tendon Complex Lesions of the Shoulder. *Am J Sports Med* 1995;23:93-98.
4. **Kim TK, Queale WS, Cosgarea AJ, McFarland EG.** Clinical features of the different types of SLAP lesions. *J Bone Joint Surg Am.* 2003;85A:66-71.
5. **Snyder SJ, Banas MP, Karzel RP.** An analysis of 140 injuries to the superior glenoid labrum. *J Shoulder Elbow Surg* 1995;4:243-248.
6. **Rodosky MW, Harner CD, Fu FH.** The role of the long head of the biceps muscle and superior glenoid labrum in anterior stability of the shoulder. *Am J Sports Med.* 1994;22: 121-130.
7. **Healey JH, Barton S, Noble P, et al.** Biomechanical evaluation of the origin of the long head of the biceps tendon. *Arthroscopy.* 2001;17(4):378-82.
8. **Sakurai G, Ozaki J, Tomita Y, et al.** Electromyographic analysis of shoulder joint function of the biceps brachii muscle during isometric contraction. *Clin Orthop.* 1998;354: 123-31.
9. **Yamaguchi K, Riew KD, Galatz LM, et al.** Biceps activity during shoulder motion: An electromyographic analysis. *Clin Orthop.* 1997;336:122-9.
10. **Mileski RA, Snyder SJ.** Superior labral lesions in the shoulder: pathoanatomy and surgical management. *J Am Acad Orthop Surg* 1998;6:121-131.
11. **Thal R.** Knotless Suture Anchor, Arthroscopic Bankart Repair Without Tying Knots, *Clin Orthop* 2001;390:42-51.
12. **O'Brien SJ, Allen, AA Coleman, SH and Drakos, MC.** The Trans-Rotator Cuff Approach to SLAP lesions: Technical Aspects for Repair and a Clinical Follow-up of 31 Patients at a Minimum of 2 years follow up. *Arthroscopy* 2002;18:372-377.
13. **Randall, KR, Harding, WG III.** Technical Note. A Safe, Easy and Inexpensive Technique for Patient Positioning in Shoulder Surgery. *Arthroscopy* 2002;18:812-814.